



## Urgent carotid stenting before cardiac surgery in a young male patient with acute ischemic stroke caused by aortic and carotid dissection

Hitno ugrađivanje stenta u karotidu pre kardiohirurške intervencije kod mladog muškarca sa akutnim ishemijskim moždanim udarom izazvanim aortnom i karotidnom disekcijom

Rade Popović\*, Sanja Radovinović-Tasić†, Siniša Rusović†, Toplica Lepić\*\*§,  
Radoje Ilić\*\*§, Ranko Raičević\*\*§, Dragana Obradović\*\*§

\*Clinic for Neurology, †Institute for Radiology, ‡Clinic for Cardiosurgery, Military Medical Academy, Belgrade, Serbia; §Faculty of Medicine of the Military Medical Academy, University of Defence, Belgrade, Serbia

### Abstract

**Introduction.** Acute aortic dissection (AD) is the most common life-threatening disorder affecting the aorta. Neurological symptoms are present in 17–40% of cases. The management of these patients is controversial. **Case report.** We presented a 37-year-old man admitted for complaining of left-sided weakness. Symptoms appeared two hours before admission. The patient had no headache, neither thoracic pain. Neurological examination showed mild confusion, left-sided hemiplegia, National Institutes of Health Stroke Scale (NIHSS) score was 10. Ischemic stroke was suspected, brain multislice computed tomography (MSCI) and angiography were performed and right intrapetrous internal carotid artery dissection noted. Subsequent color Doppler ultrasound of the carotid arteries showed dissection of the right common carotid artery (CCA). The patient underwent thoracic and abdominal MSCCT aortography which showed ascending aortic dissection from the aortic root, propagating in the brachiocephalic artery and the right CCA. Digital subtraction angiography was performed subsequently and two stents were successfully implanted in the

brachiocephalic artery and the right CCA prior to cardiac surgery, only 6 hours after admission. The ascending aorta was reconstructed with graft interposition and the aortic valve re-suspended. The patient was hemodynamically stable and with no neurologic deficit after surgery. Unfortunately, at the operative day 6, mediastinitis developed and after intensive treatment the patients died 35 days after admission. **Conclusion.** In young patients with suspected stroke and oscillatory neurological impairment urgent MSCCT angiography of the brain and neck and/or Doppler sonography of the carotid and vertebral artery are mandatory to exclude carotid and aortic dissection. The prompt diagnosis permits urgent carotid stenting and cardiosurgery. To the best of our knowledge, this is the first published case of immediate carotid stenting in acute ischemic stroke after the diagnosis of carotid and aortic dissection and prior to cardiac surgery.

### Key words:

aorta; carotid artery, internal, dissection; stroke; cardiovascular surgical procedures; stents; young adults; treatment outcome.

### Apstrakt

**Uvod.** Disekcija aorte je najčešće i po život opasno oboljenje aorte. Neurološki simptomi se javljaju kod 17–40% bolesnika. Lečenje ovih bolesnika je predmet kontroverzi. **Prikaz bolesnika.** Prikazali smo bolesnika starog 37 godina, koji je primljen u centar hitne pomoći zbog slabosti levostranih ekstremiteta. Simptomi su se javili dva sata pred prijem. Bolesnik nije imao glavobolju, ni bolove u grudima. Somatski pregled bio je bez patološkog nalaza. U neurološkom pregledu objektivizirana je laka konfuznost, plegija levostranih ekstremiteta, centralni facijalis levo, ekstenzioni plantarni odgovor levo *National Institutes of Health Stroke Scale* (NIHSS) skor bio je 10. Po-

sumnjano je na ishemijski infarkt mozga, te je odmah urađeno snimanje glave multislajsnim skenerom (MSCCT) sa angiografijom, na kome je uočena suspektna disekcija intrapetroznog dela desne unutrašnje karotidne arterije (ACI). Nakon toga urađen je dopler krvnih sudova vrata na kome je uočena disekcija desne zajedničke karotidne arterije. Urađena ekstrakranijalna MSCCT angiografija ukazala je na disekciju luka aorte koja se širila ka brahiocefaličnom stablu i desnoj zajedničkoj karotidnoj arteriji. Odmah je urađena digitalna suptrakciona angiografija i u istom aktu postavljenja su dva stenta u brahiocefalično stablo i desnu zajedničku karotidnu arteriju. Šest sati nakon prijema, zbog disekcije ascendentne aorte, bolesnik je podvrgnut operaciji, kada je rekonstruisana ascendentna aorta i

urađena resuspenzija aortnog zaliska. Šestog postoperativnog dana razvio se medijastinitis. Lečenje je pokušano visokim dozama antibiotika, međutim 35. postoperativnog dana bolesnik je preminuo. **Zaključak.** Kod mlađih bolesnika sa sumnjom na infarkt mozga i promenljivim neurološkim deficitom hitna MSCT angiografija glave i vrata ili dopler karotidnih i vertebralnih arterija su obavezni u cilju isključivanja aortne i karotidne disekcije. Brza dijagnoza omogućava hitnu ugradnju stenta u karotidu i kardiohirurgiju. Prema nama dostupnim

podacima iz literature, ovo je prvi objavljen prikaz hitne ugradnje stenta u karotidu kod akutnog infarkta mozga nakon dijagnoze karotidne i aortne disekcije, a neposredno pre kardiohirurške intervencije.

#### Ključne reči:

**aorta; a. carotis interna, disekcija; mozak, veliki, infarkt; hirurgija, kardiovaskularna, procedure; stentovi; mlade osobe; lečenje, ishod.**

## Introduction

Acute aortic dissection (AD) is the most common life-threatening disorder affecting the aorta. The incidence of AD ranges between 5 and 30 cases *per million people per year*<sup>1</sup>. The outcome of aortic dissection is frequently fatal, and many patients may die before presentation to the hospital or before diagnosis.

More than one third of all patients with aortic dissection demonstrate signs and symptoms secondary to organ system involvement<sup>2</sup>. Neurological symptoms at onset of aortic dissection are not rare, they are present in 17–40% of cases, (ischemic stroke, spinal cord ischemia, ischemic neuropathy, hypoxic encephalopathy, syncope)<sup>2</sup>, but aortic dissection remains often unrecognized as underlying cause and life threatening condition. Especially in pain-free dissections with predominant neurological symptoms diagnosis of aortic dissection can be difficult and delayed.

We presented a young patient with acute onset of left-sided hemiplegia as a sole clinical manifestation of acute aortic and carotid dissection. The patient was promptly diagnosed and underwent urgent percutaneous carotid stenting in order to stabilize neurologic deficit followed by immediate cardiac surgery repair.

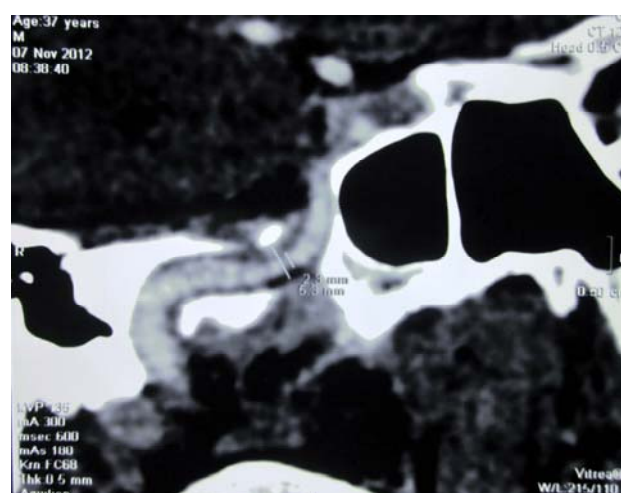
We would like to stress two issues. The first one is that all young stroke patients should have MSCT angiography of the brain and neck arteries. The second one is that prompt stenting of the carotid artery dissection in acute ischemic stroke enables surgery of aortic dissection.

## Case report

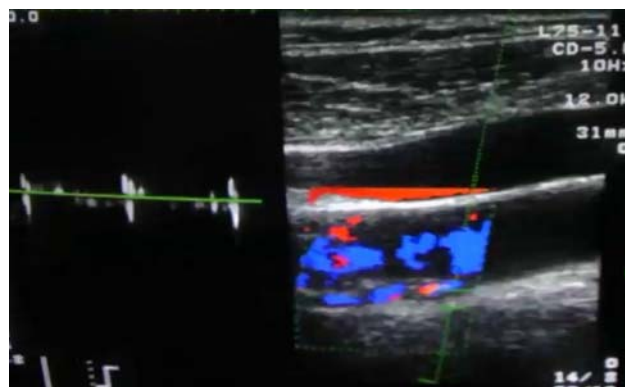
We presented a 37-year-old man admitted to the Emergency Department of Military Medical Academy (MMA) complaining of left-sided weakness. Symptoms appeared two hours before admission, after the patient woke up in the morning. He had no other complaints, nor headache, neither thoracic pain. Risk factors in the presented patient were obesity, history of hypertension and smoking. On general examination the patient was conscious, afebrile, blood pressure was 150/90 mmHg, pulse 86/min, auscultation revealed normal heart and lung sounds, ECG showed no abnormal findings. Neurological examination showed mild confusion, left-sided hemiplegia and central facial palsy on the left side with left extensor plantar response, National Institutes of Health Stroke Scale score was 10, Modified Rankin Scale (mRS) was 4. Ischemic stroke was suspected and the patient

was considered for intravenous thrombolysis though exact time of symptom onset was uncertain. Brain multislice computed tomography (MSCT) and brain MSCT angiography were performed within 45 min of admission showing no brain lesions, however right intrapetrous internal carotid artery (ICA) dissection was suspected (Figure 1).

Subsequent color Doppler ultrasound of the carotid arteries showed dissection of the right common carotid artery (CCA) (Figure 2).



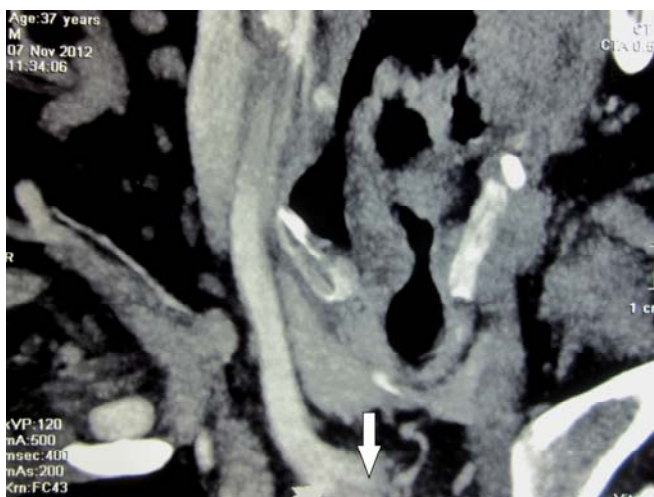
**Fig. 1 – Multislice computed tomography (MSCT) angiography of the brain. A petrous segment of the right internal carotid artery narrowed approximately 60%.**



**Fig. 2 – Doppler ultrasound of carotid arteries. Biphasic flow of the right common carotid artery.**

Meanwhile, within 3 hours from the symptom onset, there was an almost complete neurological deficit reduction, with only mild left-arm weakness persisting, NIHSS score 2. The patient underwent abdominal, thoracic and extracranial

MSCT angiography which showed ascending aortic dissection Stanford type A, propagating in the brachiocephalic artery (BCA) and the right CCA (Figure 3). Following MSCT, digital subtraction angiography (DSA) was performed and two self-expanding stents (8 × 60 mm Protege GPS self expanding peripheral stent, manufactured by EV3) inserted in the brachiocephalic artery and the right CCA with complete closure of dissection with establishing normal anterograde flow (Figure 4). Due to dissection of the ascending aorta the patient underwent emergency cardiosurgery, 8 hours after symptom onset and 6 hours after admission to the hospital. Resection of the ascending aorta and reconstruction with the artificial blood vessel by the use of graft-interpositum was performed as well as resuspension of the aortic valve. Surgery was performed in deep hypothermic circulatory arrest with antegrad cerebral perfusion, with flow of 500 ml/min, for 42 minutes. A pathohistologic sample of aortic tissue showed possible cystic medial necrosis in the aortic tissue. After the surgery, the patient was admitted to the postoperative intensive care unit. The aortic valve was competent, with aortic regurgitation 1+, compared with 3+ before the surgery. On the postoperative day 6 the patient developed mediastinitis, treated conservatively with antibiotics and general supportive measures. The patient died 35 days later due to complications of mediastinitis.



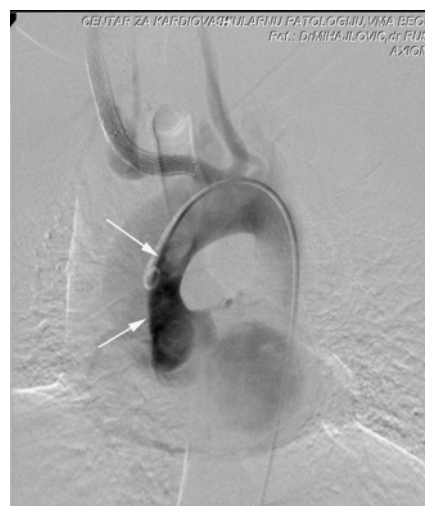**Fig. 3 – Multislice computed tomography (MSCT) angiography of carotid arteries shows dissection of the common carotid artery with subtotal prebulbar stenosis (arrows) and right internal carotid artery non-significant calcified stenosis.**

### Discussion

Our patient was presented with left-sided hemiplegia as the first and only sign of aortic and right-sided brachiocephalic artery dissection. The diagnosis was made and confirmed within the first two hours of admission, subsequent interventional radiology with brachiocephalic stenting of dissection made within three hours of admission and cardiothoracic surgery six hours after admittance to the hospital, i.e. three hours after the diagnosis was confirmed. According to the present guidelines, emergency imaging of the brain is recommended before initiating any specific therapy to treat acute ischemic

stroke (Level A, Class 1)<sup>3</sup>. A non-invasive intracranial vascular study is strongly recommended during the initial imaging evaluation of acute stroke patients if intravenous thrombolysis is contemplated for management but should not delay if thrombolysis indicated<sup>3</sup>. However, considering higher percentage of dissection as the cause of ischemic stroke in younger patients, brain and neck MSCT angiography and Doppler sonography of carotid and vertebral arteries (if MSCT is not available) should be part of mandatory diagnostic procedures in this patient population. If MSCT brain angiography had not been performed in our patient, carotid dissection would not have been suspected and further diagnostic would not have been performed, leaving aortic dissection unrecognized. Thrombolytic treatment in acute ischemic stroke related to internal carotid artery dissection has been reported to be safe and effective<sup>4</sup>. However, aortic dissection is the absolute contraindication for thrombolysis. So, in case of confirmed carotid stenosis aortic dissection has to be excluded in order to proceed with thrombolysis.

Regarding stenting of the brachiocephalic and carotid artery combined with aortic dissection surgery, there are no clear guidelines<sup>5</sup>. Sporadic case reports are published, with stenting after, or during the surgery of aortic arch (hybrid procedures)<sup>6-8</sup>, by performing temporary femoral-carotid artery bypass<sup>9</sup>, or by successful repair of the brachiocephalic artery fol-



**Fig. 4 – Digital subtraction angiography. Stanford type aortic dissection. Stents in brachiocephalic artery. Arrows show the false lumen of the aorta.**

lowed by reconstruction of the ascending aorta with the patient in profound hypothermia<sup>10</sup>. To the best of our knowledge, there has been no published report on carotid stenting in acute ischemic stroke prior cardiosurgery. The official guidelines confirm controversy over whether surgery should be performed in patients with AD type A presenting with neurological deficits<sup>5</sup>. Although commonly associated with a poor postoperative prognosis, recovery has been reported when rapid brain reperfusion is achieved<sup>5</sup>, as it was in the presented case by brachiocephalic and carotid stenting. This is the first case that such hybrid procedure, carotid stenting/cardiac surgery, has been attempted and completed in our hospital.

Surgical mortality for acute AD type A reported in different experiences from single centers or surgeons varies from 7% to 30%<sup>11</sup>. The immediate mortality rate in aortic dissection is as high as 1% *per* hour over the first 48 hours, making early diagnosis and treatment critical for survival<sup>12,13</sup>. In the International Registry of Acute Aortic Dissection, data related to symptomatic aortic dissection, median time from arrival to the emergency department and diagnosis was 4.3 hours, and from diagnosis to surgery also 4.3 hours<sup>14</sup>. Delays in recognition are mainly because of nonexistence of characteristic signs and symptoms, and delays are prolonged in non-tertiary hospitals due to lack of equipment and skilled staff. Our patient experienced neurological impairment due to non-symptomatic aortic dissection, making the diagnosis even more challenging. Nevertheless, the diagnosis was made within the 3 hours of admission, carotid stenting within 4 hours and surgery within 6 hours of admission.

Most affected patients complain of sudden, severe chest pain. Whereas most patients without neurological symptoms (94%) experience initial pain, only two-thirds of patients with neurological symptoms at the onset of dissection report a history of pain<sup>2</sup>. Our patient complained of no thoracic pain, nor headache.

The frequency of neurological involvement varies from 17% to 40%<sup>2</sup>. Neurological symptoms can be classified into different groups: ischemic stroke, spinal cord ischemia, ischemic neuropathy, and hypoxic encephalopathy. However, symptoms of acute ischemic stroke are the most common initial neurological finding. Strokes tend to be most frequently hemispheric and predominantly in the right hemisphere. Involvement of the major branches of the aortic arch varies from 20% to 43%<sup>2</sup>. Our patient was presented with signs of acute ischemic stroke of the right hemisphere and dissection of the right CCA.

Symptoms of the carotid artery dissection are grouped into triad of unilateral head, facial, or neck pain with accompanying partial Horner syndrome<sup>4</sup>. However, less than one-third of patients are presented with this classic triad<sup>4</sup>. Headache presents in 44–69% of patients and partial Horner syndrome may be found in up to 50% of patients<sup>4</sup>. In addition, approximately 5% of carotid artery dissections are asymptomatic<sup>4</sup>.

Our patient showed neither of these signs nor did he complained of any pain in neck or head.

Carotid artery dissection is the underlying cause of approximately 2.5% of strokes in all patients<sup>4</sup>. Nevertheless, it accounts for up to 20% of strokes in patients younger than 45 years<sup>4</sup>, as was our patient.

As aforementioned, in younger patients brain CT angiography, extracranial CT angiography or ultrasound of carotid arteries should be performed, although there are no official recommendations for the last two. This is especially important when such diagnostic procedures are available in medical facilities and there is no time loss as was the case with the presented patient.

Early detection of acute ischemic stroke secondary to painless aortic dissection is challenging itself, not only due to narrow 4.5 hours' time window for thrombolytic therapy, but due to possible interventional radiology and cardiosurgery procedures.

After confirming dissection, our patient underwent brachiocephalic and carotid stenting, before surgical reparation. Surgery itself is a great risk, emphasized with duration of surgery, urgency of procedure and obesity of patients. These are also risk factors for mediastinitis. Unfortunately, mediastinitis developed in the presented patient and he died 35 days after the surgery. Apart from the prompt diagnosis by the neurologist, experienced interventional radiologist capable of instant carotid stenting, availability of immediate cardiac surgery, postoperative intensive care is likewise crucial for the survival.

## Conclusion

In young patients with suspected stroke and oscillatory neurological impairment MSCT angiography of the brain and neck or Doppler sonography of the carotid and vertebral arteries are mandatory to exclude carotid and aortic dissection especially if thrombolytic treatment is contemplated. The prompt diagnosis permits urgent carotid stenting and cardiosurgery. To the best of our knowledge, this is the first published case of immediate carotid stenting after the diagnosis of carotid and aortic dissection and prior to cardiosurgery.

## R E F E R E N C E S

1. *Braverman AC*. Aortic dissection: prompt diagnosis and emergency treatment are critical. *Cleve Clin J Med* 2011; 78(10): 685–96.
2. *Gaul C, Dietrich W, Friedrich I, Sirch J, Erbguth FJ*. Neurological symptoms in type A aortic dissections. *Stroke* 2007; 38(2): 292–7.
3. *Jauch EC, Saver JL, Adams HP, Bruno A, Connors JJ, Demaerschalk BM, et al*. Guidelines for the Early Management of Patients With Acute Ischemic Stroke: A Guideline for Healthcare Professionals From the American Heart Association/American Stroke Association. *Stroke* 2013; 44(3): 870–947.
4. *Patel RR, Adam R, Maldjian C, Lincoln CM, Yuen A, Armeja A*. Cervical carotid artery dissection: current review of diagnosis and treatment. *Cardiol Rev* 2012; 20(3): 145–52.
5. *Erbel R, Aboyans V, Boileau C, Bossone E, Bartolomeo RD, Eggebrecht H, et al*. 2014 ESC Guidelines on the diagnosis and treatment of aortic diseases: Document covering acute and chronic aortic diseases of the thoracic and abdominal aorta of the adult. The Task Force for the Diagnosis and Treatment of Aortic Diseases of the European Society of Cardiology (ESC). *Eur Heart J* 2014; 35(41): 2873–926.
6. *Lentini S, Tancredi F, Benedetto F, Gaeta R*. Type A aortic dissection involving the carotid arteries: carotid stenting during open aortic arch surgery. *Interact Cardiovasc Thorac Surg* 2009; 8(1): 157–9.
7. *Roseborough GS, Murphy KP, Barker PB, Sussman M*. Correction of symptomatic cerebral malperfusion due to acute type I aortic dissection by transcarotid stenting of the innominate and carotid arteries. *J Vasc Surg* 2006; 44(5): 1091–6.

8. *Cardaioli P, Rigatelli G, Giordan M, Faggian G, Chinaglia M, Roncon L.* Multiple carotid stenting for extended thoracic aorta dissection after initial aortic surgical repair. *Cardiovasc Revasc Med* 2007; 8(3): 213–5.
9. *Munakata H, Okada K, Kano H, Izumi S, Hino Y, Matsumori M, et al.* Controlled earlier reperfusion for brain ischemia caused by acute type A aortic dissection. *Ann Thorac Surg* 2009; 87(4): 27–8.
10. *Micovic S, Nezic D, Vukovic P, Jovanovic M, Lozruk B, Jagodic S, et al.* Concomitant Reconstruction of Arch Vessels during Repair of Aortic Dissection. *Tex Heart Inst J* 2014; 41(4): 421–4.
11. *Trimarchi S, Nienaber CA, Rampoldi V, Myrmet T, Suzuki T, Mehta RH, et al.* Contemporary results of surgery in acute type A aortic dissection: The International Registry of Acute Aortic Dissection experience. *J Thorac Cardiovasc Surg* 2005; 129(1): 112–22.
12. *Braverman AC.* Acute aortic dissection: clinician update. *Circulation* 2010; 122(2): 184–8.
13. *Criado FJ.* Aortic dissection: a 250-year perspective. *Tex Heart Inst J* 2011; 38(6): 694–700.
14. *Harris KM, Strauss CE, Eagle KA, Hirsch AT, Isselbacher EM, Tsai TT, et al.* Correlates of delayed recognition and treatment of acute type A aortic dissection: the International Registry of Acute Aortic Dissection (IRAD). *Circulation* 2011; 124(18): 1911–8.

Received on April 2, 2015.

Revised on April 29, 2015.

Accepted on May 4, 2015.

Online First September, 2015.