



## Flail chest in a polytraumatized patient: management and treatment – case report

### Zbrinjavanje politraumatizovanog bolesnika sa torakalnim kapkom

Bojan Milošević<sup>\*†</sup>, Slobodan Milisavljević<sup>\*†</sup>, Nikola Dončić<sup>\*</sup>, Miloš Arsenijević<sup>\*†</sup>,  
Stanko Mrvić<sup>\*</sup>, Dragan Stojković<sup>\*</sup>, Nebojša Marić<sup>‡</sup>,  
Marko Spasić<sup>\*†</sup>

Clinical Center Kragujevac, <sup>\*</sup>Clinic for General and Thoracic Surgery, Kragujevac, Serbia; University of Kragujevac, <sup>†</sup>Faculty of Medical Sciences, Kragujevac, Serbia; Military Medical Academy, <sup>‡</sup>Clinic for Thoracic Surgery, Belgrade, Serbia

#### Abstract

**Introduction.** Management of a polytraumatized patient is a problem that requires a multidisciplinary approach, in order to optimise patient's outcome. The purpose of this study was to show the approach in the treatment of a patient with a severe life-threatening polytrauma, including a personalized healthcare approach with the positive outcome after the inadequate initial treatment. **Case report.** We presented a case of a young polytraumatized patient with trauma as a result of road traffic accident. The patient had chest, abdominal and right arm injuries. He was diagnosed of hepatic rupture with conusation and retroperitoneal hematoma and the patient underwent liver tamponade. Chest trauma due to bilateral serial rib fracture with flail chest was treated by chest drainage. After the adequate multidisciplinary interventions for the patient, the patient was discharged. **Conclusion.** This case report is of great importance since it shows that severe polytraumatized patients with bad initial prognosis can successfully receive a life-saving treatment.

#### Key words:

multiple trauma; thoracic injuries; liver; humeral fractures; diagnostic techniques and procedures; suction; respiration, artificial.

#### Apstrakt

**Uvod.** Zbrinjavanje politraumatizovanog bolesnika je problem kome se mora pristupiti multidisciplinarno u cilju dobijanja najboljeg mogućeg ishoda. Cilj rada bio je da prikaže lečenje bolesnika sa životno ugrožavajućom politraumom, personalizovanim pristupom u lečenju sa uspešnim ishodom posle neadekvatnog inicijalnog lečenja. **Prikaz slučaja.** Prikazan je slučaj mladog politraumatizovanog bolesnika koji je povrede zadobio kao vozač motora. Dominantne povrede bile su grudnog koša, trbuha i desne ruke. Zbog rupture jetre sa konkvacijom i retroperitonealnim hematomom učinjena je tamponada jetre. Povreda grudnog koša uzrokovana bilateralnom serijskom frakturom rebara i torakalnim kapkom zbrinuta je obostranom grudnom drenažom. Nakon adekvatnog multidisciplinarnog hirurškog lečenja bolesnik je otpušten na kućno lečenje. **Zaključak.** Značaj prikaza ovog slučaja je u tome što pokazuje da se i teška politrauma sa inicijalno visokim trauma skorom i lošom prognozom može brzo i adekvatno lečiti i za rezultat imati očuvanje života povređenog.

#### Ključne reči:

povrede, multiple; toraks, povrede; jetra, povrede; humerus, prelomi; dijagnostičke tehnike i procedure; aspiracija, mehanička; disanje, mehaničko.

#### Introduction

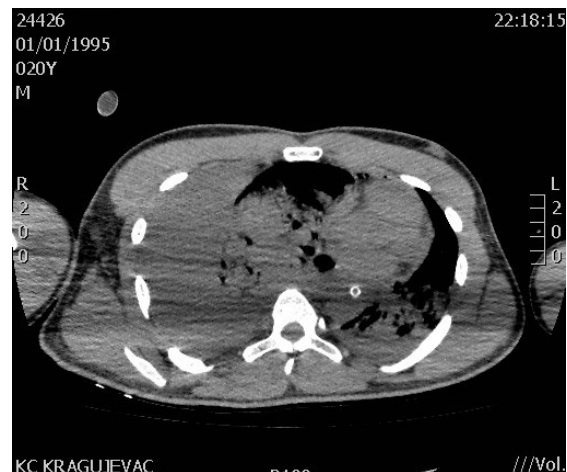Management of a polytraumatized patient is a problem that requires a multidisciplinary approach, in order to optimise patient's outcome. It involves a cohesive group of individuals working together with polytraumatized patient, with minimal waste of time, from the moment of admission to a health facility to the moment of release. The important milestones

in the implementation of a systematic and structured care for traumas dates back to 1878, when the first Advanced Trauma Life Support (ATLS) course was conducted<sup>1-3</sup>. The role of trauma surgical procedures is not to provide a definitive anatomic reconstruction but to provide a normal physiological function of damaged tissues and organs. The most common surgical procedures include hemostasis, decontamination of injured body cavities and the rapid closure

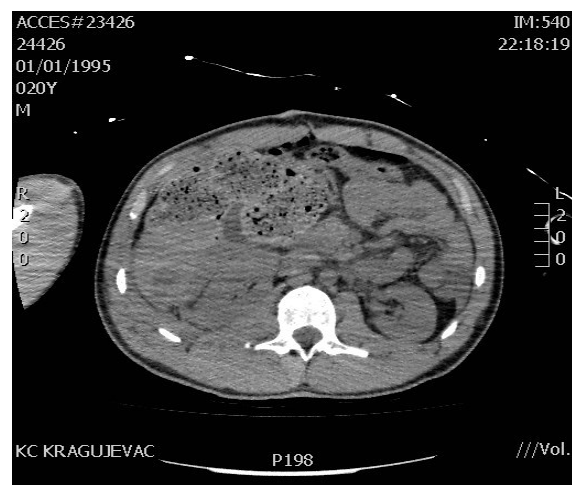
of surgical wounds<sup>4-6</sup>. Resuscitation and following surgical treatment may not be life-saving procedures in polytraumatized patients – bodily functions may fail to return to normal ones which results in death, permanent disability, scarring, pain, as well as in the difficulties that affect all spheres of life (physical, psychological, social, and financial). Therefore, we should focus on prevention of trauma and pay more attention to the resources directed to work on the prevention. The purpose of this study was to show the approach in the treatment of a patient with a severe life-threatening polytrauma, including a personalized healthcare approach with the positive outcome, after the inadequate initial treatment.

### Case report

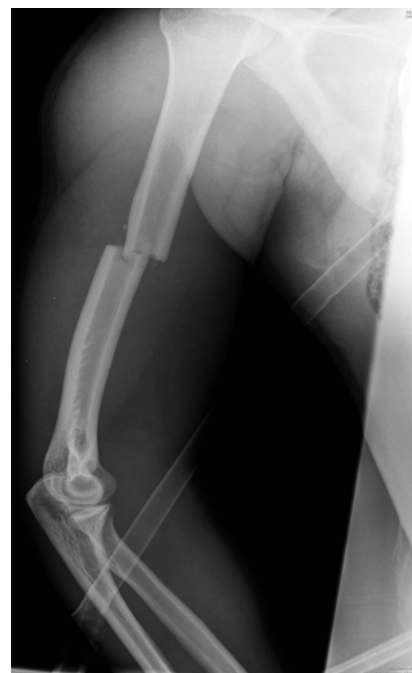The male patient, age 20, was admitted to Clinical Center Kragujevac with the injuries he sustained in a traffic accident. On admission the patient was intubated, without spontaneous breathing, unconscious, hemodynamically unstable, with blood pressure 100/65 mm Hg, heart rate of 110/min, blood oxygen saturation (SpO<sub>2</sub>) 99%. Arterial blood gas analysis (also done on admission) revealed the following results: partial pressure of oxygen (PaO<sub>2</sub>) 7.4 kPa; partial pressure of carbon dioxide (PaCO<sub>2</sub>) 10.7 kPa, Bicarbonate (HCO<sub>3</sub>) 26.6 mmol/L; Glasgow coma score (GCS) was 7, Injury Severity Score (ISS) was 50. There were the clinical signs of flail chest. He was previously treated in the Regional Health Centre. Diagnosis was hepatic rupture with conqusation and retroperitoneal hematoma and the patient underwent liver tamponade with 6 abdominal compressions; operative wound was sutured without placing an abdominal drains. During the initial treatment the patient received 6 units of blood. The volume and the seriousness of the injury required a multi disciplinary treatment approach. Computed tomography (CT) scan of endocranium showed normal findings. A chest CT scan showed a serial broken ribs on both sides with massive right sided traumatic hemothorax, left sided traumatic pneumothorax and massive lung contusion on both sides (Figure 1). CT of the abdomen showed: liver morphology wiped out in the posterior parts, unclearly contoured with conqusated tissue (the rest of the liver was heterogeneous structure but a clear morphology); compresses made sufficient tamponade (Figure 2); rupture of the right kidney with the formation of retroperitoneal hematoma; a larger amount of hemorrhagic contents intraperitoneally. Orthopaedic clinical and radiographic examination showed fracture of the right humerus (Figure 3). During 60 minutes after the admission to the hospital the CT findings showed that the immediate surgical treatment was necessary. The patient received 4 blood units more in our hospital and there was risk of massive transfusion. Drainage of the right pleural space was performed, and it evacuated about 3,000 mL hemorrhagic content; drainage of the left pleural space evacuated the air and about 200 mL of blood (Figure 4). Relaparotomy was immediately performed and an irregular laceration of the right lobe of the liver with elements of conqusation and active bleeding from the laceration was identified. The patient underwent repeated liver tamponade



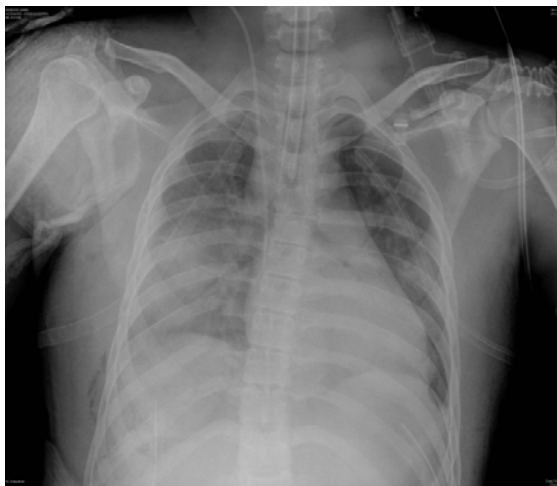**Fig. 1 – A chest computed tomography scan showed a serial broken ribs on both sides with massive right sided traumatic hemothorax, left sided traumatic pneumothorax and massive lung contusion on both sides.**



**Fig. 2 – Computed tomography scan image of perihepatic packing after first operation.**



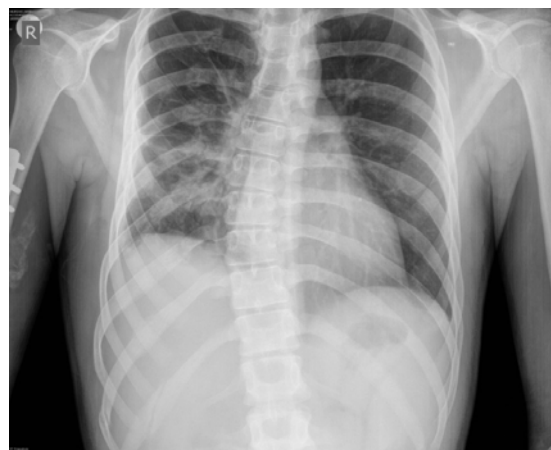**Fig. 3 – Fracture of the right humerus.**



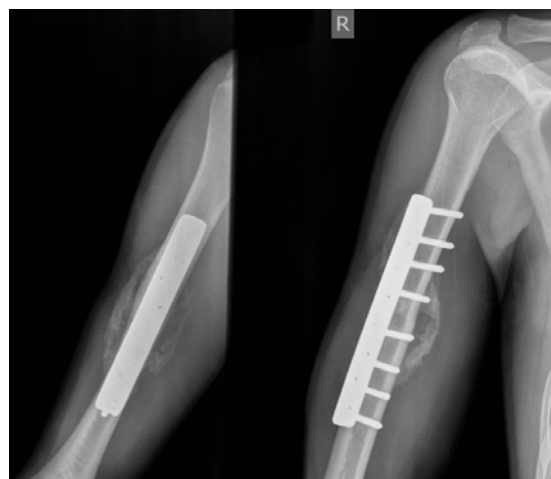**Fig. 4 – Drainage of both pleural cavities due to right sided hemothorax and left sided pneumothorax.**

with sterile perforated bags with two abdominal compressions, two subphrenically and two subhepatically placed, and it was managed to stop the bleeding from the liver. Due to the existence of retroperitoneal hematoma and CT findings of ruptured kidney, the urologist eliminated the need for surgical treatment of kidney infringement. The external fixation of the fracture of the right humerus was performed with the plaster splint by the orthopedists. After the liver tamponade hepatogram was aspartate aminotransferase (AST) 348 IU/L (ref. range 0 – 40 IU/L), alanine aminotransferase (ALT) 408 IU/L (ref. range 0–40 IU/L), total bilirubin: 30.7 umol/L (ref. range 5,0–21 umol/L), direct bilirubin: 8.3 umol/L (ref. range 0,1–3,4 umol/L). The patient was connected to a breathing machine, a mechanical ventilation system, thus achieving an adequate gas exchange and an internal stabilization of the flail chest. Arterial blood gas analysis after the chest drainage revealed the following levels: PaO<sub>2</sub> 17.2 kPa; PaCO<sub>2</sub> 5.7 kPa; HCO<sub>3</sub> 33.1 mmol/L. The patient received a greater number of blood units and blood derivatives: 20% albumin, platelet concentrate, cryoprecipitate. The adequate antibiotic therapy was determined according to the results of regularly taken swabs from surgical wounds, the thoracic and abdominal drains and biological samples for microbiological examination. On the seventh day of hospitalization, laparotomy was carried out in order to remove liver tamponade. There were no signs of active bleeding in the liver. Retroperitoneal hematoma was in regression. Hepatogram after the tamponade removal was AST 105 IU/L; ALT 104 IU/L; total bilirubin: 20.3 umol/L; direct bilirubin: 9.1 umol/L. On the 12th day of hospitalization thoracic drain on the left side of the chest was removed and control radiography registered the complete expansion of the left lung. The patient required long-term mechanical ventilation, and tracheostomy was performed on the 13th day of hospitalization. On the 21st day of hospitalization thoracic drain on the right side of the chest was removed. Regular radiographic examinations revealed lung reexpansion in the presence of contusion lesions (Figure 5). Conservative treatment of the fracture of the right humerus did not result in healing, and on the 25th day of hospitalization, dynamic compression plate

(DCP) osteosynthesis of 8 holes was performed and cortical screws were placed with deliberation radial nerve (Figure 6).

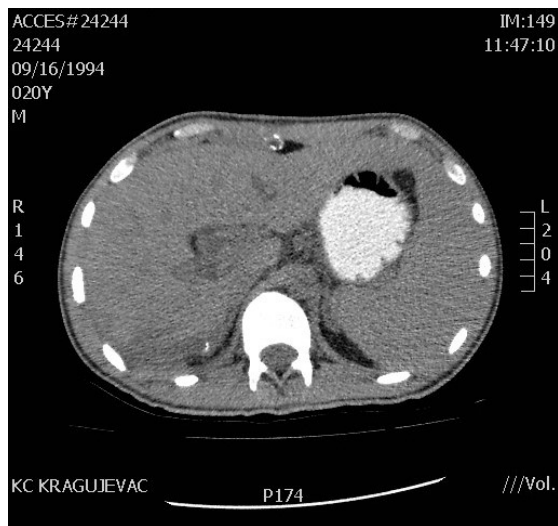


**Fig. 5 – Complete reexpansion of the lung in the presence of contusion lesions.**



**Fig. 6 – Humerus after plate osteosynthesis of 8 holes and cortical screws.**

On the 26th day of hospitalization the treatment of the patient included the physical therapy and electrostimulation for radial nerve lesions verified before the osteosynthesis. On the 27th day of hospitalization, the patient was removed from mechanical ventilation. Tracheal cannula was removed, too. Tracheostoma was healing *per secundam*. The patient was taken to the Department of Thoracic Surgery for further observation, after a 30-day-stay in the Intensive Care Unit (ICU). Radiographic examinations of the chest registered rib fractures repairs and almost complete regression of lesions was in the lung parenchyma was found. Arterial blood gas analysis during spontaneous breathing: PaO<sub>2</sub>:12.3 kPa; PaCO<sub>2</sub> 5.8 kPa; HCO<sub>3</sub> – 23 mmol/L. Control CT scan performed on the 23rd day after the removing liver packs showed normal findings (Figure 7). We continued with physical therapy that led to regression of lesions of radial nerve. At discharge, neurological status of the patient's right hand – inability to dorsiflex the hand and inability to abduct the thumb. Thirty five days after the hospital treatment, the patient was discharged and recommended to continue to attend the rehabilitation programme.



**Fig. 7 – Computed tomography scan image of the liver on the 23rd day after removing liver packs with no signs of active bleeding.**

### Discussion

The multiple injuries with thoracic trauma jeopardize the patient's status significantly. Polytrauma associated with thoracic injuries is found with blunt trauma and is usually related to road traffic injury. In most cases thoracic trauma can be managed without thoracotomy. This fact should not be taken for granted. Each patient with thoracic trauma requires urgent and qualified assessment of severity of injuries as well as the certain actions and measures in order to manage the injuries and therefore to reduce the risk of fatal outcome<sup>7</sup>.

CT diagnostics provides the identification and grading of injured organs and the quantification of fluid or blood in the cavities. This allows non-surgical treatment of stable patients, thus reducing the rate of nontherapeutic surgery<sup>8-10</sup>. Although thoracic trauma occupies approximately 10% to 15% of all traumas, the mortality rate of thoracic trauma is very high, estimated at 25%. Rib fracture is the most common injury in thoracic trauma<sup>11</sup>, but only 6% to 12% of trauma patients complain only of rib fracture – it is common for trauma patients to experience other organ injuries<sup>12</sup>. The increased number of fractured ribs increases the level of injury and its mortality rate<sup>13</sup>. Although the frequency of intraabdominal injury did not increase with the number of rib fractures, as shown in this study, the frequency of intraabdominal injuries requiring surgical treatment did<sup>14</sup>. The liver injury we identified, according to Moore, was classified as grade III. Retamponade was performed due to hemodynamic instability, massive blood loss in the pleural space after chest tube placement and the risk of massive blood transfusions. After seven days we removed liver tamponade. The recent studies recommend relaparotomy after liver packing within 48 hours,<sup>15</sup> but in our case this could not be done earlier because of the risk of liver hemorrhage and the risk of massive transfusion. Caruso et al.<sup>16</sup> shows that removing liver tamponade up to 72 hours reduced the risk of rebleeding. Although the retamponade was removed 7 days after the surgery,

there were not any complications of perihepatic tamponade in this period.

The current treatment of severe chest wall injuries such as flail chest causing instability of chest wall with paradoxical breathing with hypoventilation, disorders of arterial blood-gas (ABG) concentration levels and respiratory insufficiency, includes: nonsurgical management *via* intubation and intermittent positive pressure ventilation (internal pneumatic splint), analgesia, pulmonary toilet, and chest physiotherapy<sup>17-19</sup>. After initial treatment of chest trauma in our patients with both side drainage, although it was evacuated 3,000 mL of blood content from right side (hematocrit of this content was lower than that of the venous blood), the patient's respiratory status was stable and drained fluid was 50 mL and less during the first hour of post-drainage, so we gave up thoracotomy. During the first week of hospitalization, the primary goals of the treatment were the stabilization of hemodynamic parameters, improvement of respiratory function, improvement in hematological status, infection control and flail chest stabilization (flail resulted from mutual serial rib fractures). During the treatment there were no pleural complications. There are methods for flail chest surgical fixation and studies demonstrating the benefit of surgical treatment of severe chest wall injuries<sup>20-24</sup>, but they are not widely accepted due to the lack of evidence. Flail chest treatment requires long-term mechanical ventilation. The type of mechanical ventilation that was used on our patient was intermittent positive pressure ventilation (IPPV) with positive end-expiratory pressure (PEEP). Early tracheostomy, compared to conducting tracheostomy after prolonged endotracheal intubation (longer than 14 days), reduced the incidence of pneumonia, duration of ventilatory dependence, ICU length of stay and tracheal complication rates<sup>25-28</sup>.

Taking into account the available literature and current treatment guidelines, we treated this patient as described.

### Conclusion

The management of each polytraumatized patient is based on the good clinical practice guide, though specific modifications of the approach are needed due to the severity of injuries and degree of organ systems damage, as it was shown in the case of the treatment of our patient and thoroughly explained in the report. Trauma is best managed by a team approach (there is no "I" in trauma). A thorough primary and secondary survey is key to identify life threatening injuries and to give adequate treatment. Once a life threatening injury is discovered, intervention should not be delayed.

### Acknowledgement

We would like to thank Miss Sanja Dugic for her help in English editing of the text. The part of this research is supported by the Ministry of Education, Science and Technological Development of the Republic of Serbia, Grant No III41007.

## R E F E R E N C E S

- American College of Surgeon – Committee on Trauma. 2010. [cited 2015 Jun 15]. Available from: <http://www.facs.org/trauma/atls/history.html>
- Carmont MR. The Advanced Trauma Life Support course: A history of its development and review of related literature. *Postgrad Med J* 2005; 81(952): 87–91.
- Kortbeek JB, Al Turki SA, Ali J, Antoine JA, Bouillon B, Brasel K, et al. Advanced trauma life support, 8th edition, the evidence for change. *J Trauma* 2008; 64(6): 1638–50.
- Lee JC, Peitzman AB. Damage-control laparotomy. *Curr Opin Crit Care* 2006; 12(4): 346–50.
- Blackbourne LH. Combat damage control surgery. *Crit Care Med* 2008; 36(7 Suppl): S304–10.
- Cirocchi R, Abraha I, Montedori A, Farinella E, Bonacini I, Tagliabue L, et al. Damage control surgery for abdominal trauma. *Cochrane Database Syst Rev* 2010; (1): CD007438.
- Kish G, Kozloff L, Joseph WL, Adkins PC. Indications for early thoracotomy in the management of chest trauma. *Ann Thorac Surg* 1976; 22(1): 23–8.
- Federle MP, Goldberg HI, Kaiser JA, Moss AA, Jeffrey RB, Mall JC. Evaluation of abdominal trauma by computed tomography. *Radiology* 1981; 138(3): 637–44.
- Kearney PA, Vahay T, Burney RE, Glazer G. Computed tomography and diagnostic peritoneal lavage in blunt abdominal trauma. Their combined role. *Arch Surg* 1989; 124(3): 344–7.
- Liu M, Lee CH, Peng FK. Prospective comparison of diagnostic peritoneal lavage, computed tomographic scanning, and ultrasonography for the diagnosis of blunt abdominal trauma. *J Trauma* 1993; 35(2): 267–70.
- Gabram SG, Schwartz RJ, Jacobs LM, Lawrence D, Murphy MA, Morrow JS, et al. Clinical management of blunt trauma patients with unilateral rib fractures: A randomized trial. *World J Surg* 1995; 19(3): 388–93.
- Shorr RM, Crittenden M, Indeck M, Hartunian SL, Rodriguez A. Blunt thoracic trauma. Analysis of 515 patients. *Ann Surg* 1987; 206(2): 200–5.
- Bergeron E, Lavoie A, Clas D, Moore L, Ratte S, Tetreault S, et al. Elderly trauma patients with rib fractures are at greater risk of death and pneumonia. *J Trauma* 2003; 54(3): 478–85.
- Park S. Clinical Analysis for the Correlation of Intra-abdominal Organ Injury in the Patients with Rib Fracture. *Korean J Thorac Cardiovasc Surg* 2012; 45(4): 246–50.
- Doklestić K, Stefanović B, Gregorić P, Ivančević N, Lončar Z, Jovanović B, et al. Surgical management of AAST grades III-V hepatic trauma by Damage control surgery with perihepatic packing and Definitive hepatic repair-single centre experience. *World J Emerg Surg* 2015; 10: 34.
- Caruso DM, Battistella FD, Owings JT, Lee SL, Samaco RC. Perihepatic packing of major liver injuries: complications and mortality. *Arch Surg* 1999; 134(9): 958–62; discussion 962–3.
- Lafferty PM, Anavian J, Will RE, Cole PA. Operative treatment of chest wall injuries: Indications, technique, and outcomes. *J Bone Joint Surg Am* 2011; 93(1): 97–110.
- Nirula R, Diaz JJ, Trunkey DD, Mayberry JC. Rib fracture repair: Indications, technical issues, and future directions. *World J Surg* 2009; 33(1): 14–22.
- Simon B, Ebert J, Bokhari F, Capella J, Emboff T, Hayward T 3rd, et al. Management of pulmonary contusion and flail chest: An Eastern Association for the Surgery of Trauma practice management guideline. *J Trauma Acute Care Surg* 2012; 73(4): 351–61.
- Engel C, Krieg JC, Madey SM, Long WB, Bottlang M. Operative chest wall fixation with osteosynthesis plates. *J Trauma* 2005; 58(1): 181–6.
- Grametzny A, Abd El-Aal M, Emam E, Shalaby A, Boseila A. Surgical versus conservative treatment of flail chest. Evaluation of the pulmonary status. *Interact Cardiovasc Thorac Surg* 2005; 4(6): 583–7.
- Ahmed Z, Mohyuddin Z. Management of flail chest injury: Internal fixation versus endotracheal intubation and ventilation. *J Thorac Cardiovasc Surg* 1995; 110(6): 1676–80.
- Tanaka H, Yukioka T, Yamaguti Y, Shimizu S, Goto H, Matsuda H, et al. Surgical stabilization of internal pneumatic stabilization? A prospective randomized study of management of severe flail chest patients. *J Trauma* 2002; 52(4): 727–32.
- Nirula R, Allen B, Layman R, Falimirski ME, Somberg LB. Rib fracture stabilization in patients sustaining blunt chest injury. *Am Surg* 2006; 72(4): 307–9.
- Gaynor EB, Greenberg SB. Untoward sequelae of prolonged intubation. *Laryngoscope* 1985; 95(12): 1461–7.
- Johnson SB, Kearney PA, Barker DE. Early criteria predictive of prolonged mechanical ventilation. *J Trauma* 1992; 33(1): 95–100.
- Rodriguez JL, Steinberg SM, Luchetti FA, Gibbons KJ, Taberi PA, Flint LM. Early tracheostomy for primary airway management in the surgical critical care setting. *Surgery* 1990; 108(4): 655–9.
- Agle SC, Kao LS, Moore FA, Gonzalez EA, Vercrusse GA, Todd RS. Early predictors of prolonged mechanical ventilation in major torso trauma patients who require resuscitation. *Am J Surg* 2006; 192(6): 822–7.

Received on December 07, 2015.

Revised on March 25, 2016.

Accepted on April 11, 2016.

Online First May, 2016.