



Magnets ingestion as a rare cause of ileus in adults: a case report

Progutani magneti kao redak uzrok ileusa kod odraslih

Krstina Doklešćić*†, Zlatibor Lončar*†, Bojan Jovanović†‡, Jelena Veličković†‡

Clinical Center of Serbia, *Clinic for Emergency Surgery, ‡Department for Anaesthesiology, Belgrade, Serbia; University of Belgrade, †Faculty of Medicine, Belgrade, Serbia

Abstract

Introduction. Magnetic foreign bodies are harmless when ingested as a single object. However, if numerous of individual magnets are ingested at certain intervals, one after the other, they may attract each other through the bowel wall and cause severe bowel damage. **Case report.** We reported a case of a man, age 21, who swallowed 2 very small magnets, presented with clinical and radiographic signs of acute bowel obstruction and intestinal fistula. The cause of obstruction was detected during laparotomy. At laparotomy, one magnet was found in the proximal jejunum and the other in the distal ileum, strongly attracting each other followed by small bowel twisting around this point of rotation, causing a complete small bowel obstruction with strangulation and jejuno-ileal fistula. The intestinal segments were devolvulated and both intestine perforations were primarily sutured. The patient recovered successfully after the surgery and was discharged 5 days after the laparotomy. **Conclusion.** Patients who ingested magnetic objects must be seriously considered and emergency laparotomy should be performed to prevent serious gastrointestinal complications.

Key words:

foreign bodies; magnetics; intestinal obstruction; digestive system surgical procedures.

Apstrakt

Uvod. Progutano magnetno strano telo je bezazleno ukoliko je pojedinačno. Kod gutanja većeg broja pojedinačnih magnetata u vremenskim razmacima oni se mogu međusobno snažno privući kroz zid creva i izazvati ozbiljna oštećenja. **Prikaz bolesnika.** Prikazali smo slučaj 21-godišnjeg muškarca koji je, nakon što je progutao dva mala magnetata, razvio kliničke i radiografske znake akutne crevne okluzije i intestinalne fistule. Uzrok ileusa detektovan je tek tokom laparotomije. Pri laparotomiji jedan magnet pronađen je u vijuzi proksimalnog jejunuma, a drugi u distalnom ileumu. Bili su snažno međusobno privučeni, sa uvrtanjem preostalih vijuga tankog creva oko formirane tačke rotacije, uzrokujući kompletnu crevnu opstrukciju sa strangulacijom tankog creva i jejuno-ilealnom fistulom. Crevne vijuge su oslobođene i mesta perforacije su zbrinuta primarnom suturom creva. Oporavak je protekao bez komplikacija. Bolesnik je otpušten iz bolnice petog postoperativnog dana. **Zaključak.** Ukoliko je pacijent progutao više pojedinačnih magnetata i razviju se znaci akutne intestinalne okluzije, potrebna je brza hirurška intervencija da bi se sprečile ozbiljne komplikacije.

Ključne reči:

strana tela; magnetika; creva, opstrukcija; hirurgija digestivnog sistema, procedure.

Introduction

In adult population swallowing foreign bodies (FB) is less common than in children, but it is possible as accidental ingestion or ingestion in mentally ill patients. Reaching pylorus it usually can pass through the intestine and if it reaches the colon, the patient can expel them spontaneously by defecation. Nevertheless swallowed FB can lead to severe abdominal complications in < 1%¹. A danger in FB ingestion exists if a clinician does not think about swallowing FB or when the FB is difficult to detect by commonly used diagno-

stic methods. Adults swallow, usually accidentally, fish bones, chicken bones, parts of tools being held in the mouth, toothpicks or needles². Among swallowed FB the most dangerous are sharp objects, large objects, toxic FB, button batteries and magnets^{3,4}.

Magnetic FB are seemingly harmless but they are very dangerous if patient swallows several individual magnets at certain intervals, one after the other. In this case, magnets attract each other through the walls of hollow abdominal organs and their contact leads to intestinal wall ischemia and necrosis³⁻⁶. Magnets can be seen on radiographs, but the di-

agnosis is usually delayed if patient does not give information that he/she has swallowed magnets. Significant sign of the magnet presence is the FB shadow that does not change the position of the repeated follow-up radiography in patients with worsening abdominal symptoms^{6, 7}. When multiple swallowing of magnets at certain sequences is suspected, patient requires emergency surgical treatment⁸.

The goal of this report was to point out a rare cause of acute intestinal obstruction in previously healthy young man, who has never had prior abdominal surgery which occurred when he swallowed two or more magnets at certain intervals.

Case report

A 21 years-old man with severe abdominal pain, nausea and vomiting was admitted to the Clinic for Emergency Surgery Clinical Center of Serbia, Belgrade. His symptoms started suddenly about 12 hours before arriving to the hospital. He had no previous abdominal surgery, no history of malignancy or hereditary diseases. On admission, the patients vital signs were stable. Physical examination showed distended and tender abdomen without peritoneal signs. Auscultation detected weakening peristaltic rushes. Rectal examination was regular. Laboratory analyses showed leucocytosis ($13 \times 10^9/L$). Ultrasound (US) of the abdomen showed a moderate amount of free intraperitoneal liquid. First abdominal radiograph demonstrated a several air-fluid levels of small bowel, without pneumoperitoneum (Figure 1a). Unexpectedly, abdominal radiography revealed a shadow of the foreign body presented in the middle abdomen region (Figure 1a). However, the patient denied having swallowed a foreign body. As there was no evidence of serious complications, the initial treatment was consisted of fluid

resuscitation and placement of a nasogastric tube. After a few hours, physical examination showed distended abdomen with guarding and rebound tenderness. A follow-up abdominal radiograph showed the object in an unchanged position, but demonstrated increased bowel distension with air-fluid levels and signs of ileus (Figure 1b).

The patients condition was rapidly deteriorated and clinical as well as radiological signs pointed to an acute intestinal obstruction, so the laparotomy was indicated. The laparotomy performed through a middle incision, revealed intestinal segments volvulated 30 cm distal to the Treitz ligament and distal ileum. The cause of obstruction was discovered only after the release of intestinal segments. Surprisingly, two small magnetic balls were found: one was set in the proximal jejunal loop 20 cm distal to the ligament of Treitz and the other in the distal ileum 20 cm proximal from Bauchini valve, with small bowel twisting around this point of rotation, causing a complete small bowel obstruction and strangulation (Figure 2). The strangulated bowel between these areas was not necrotic, but bowel loops proximal to occlusion were edematous and succulent. In addition, the magnetic balls connected through the bowel wall were leading to necrosis and the formation of a jejuno-ileal fistula (Figure 2a). The intestinal segments were devolvulated and both perforations were primarily sutured. After surgical removal magnets were measured and each magnetic ball was 3 mm in size (Figure 3). The patient successfully recovered after the surgery, without complications during postoperative course. He was discharged from hospital 5 days after laparotomy. The patient did not know that he had swallowed magnets; he only remembered that he had kept pieces of jewelry in his mouth, finding out after re-examination that two small parts were missing.

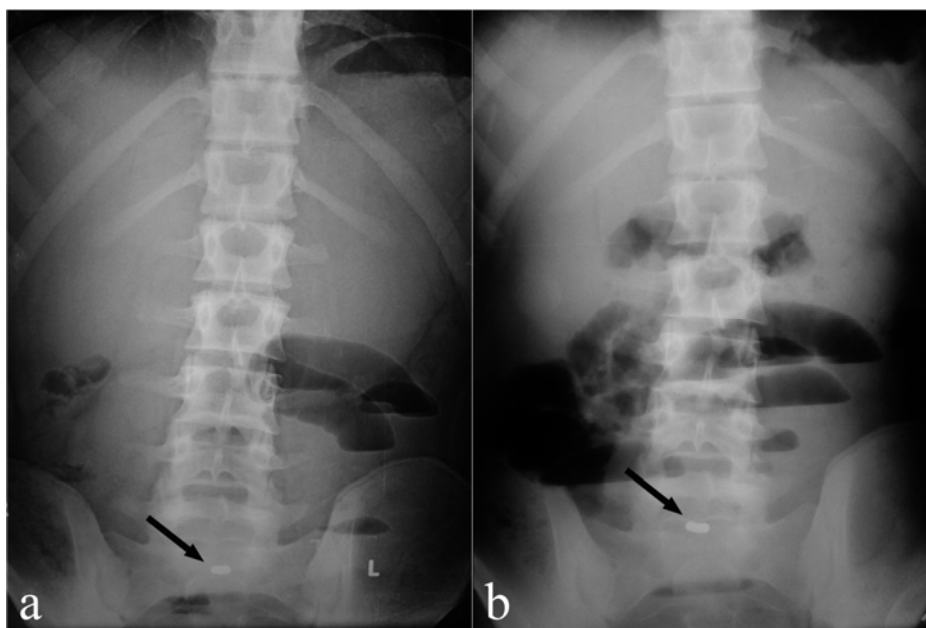


Fig. 1 – Abdominal radiography performed: a) on admittance showing a several air-fluid levels and foreign body (black arrow); b) after several hours showing a radiographic signs of small bowel obstruction and foreign body in an unchanged position (black arrow).

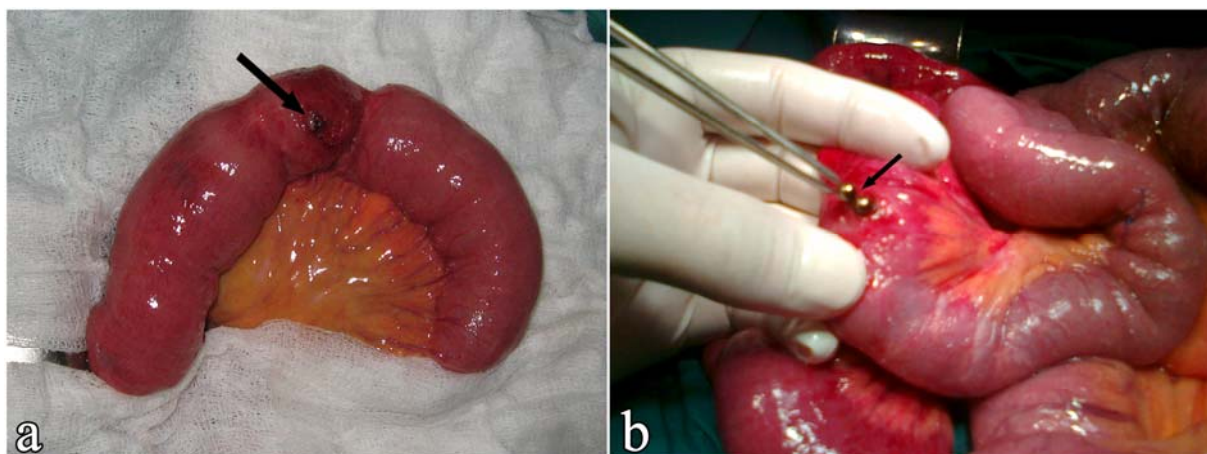


Fig. 2 – Intraoperative photograph showing: a) jejunal loop containing foreign body and local necrosis of the bowel wall (black arrow); b) the cause of obstruction after the release of intestinal segments [we found two magnetic balls (black arrow)].

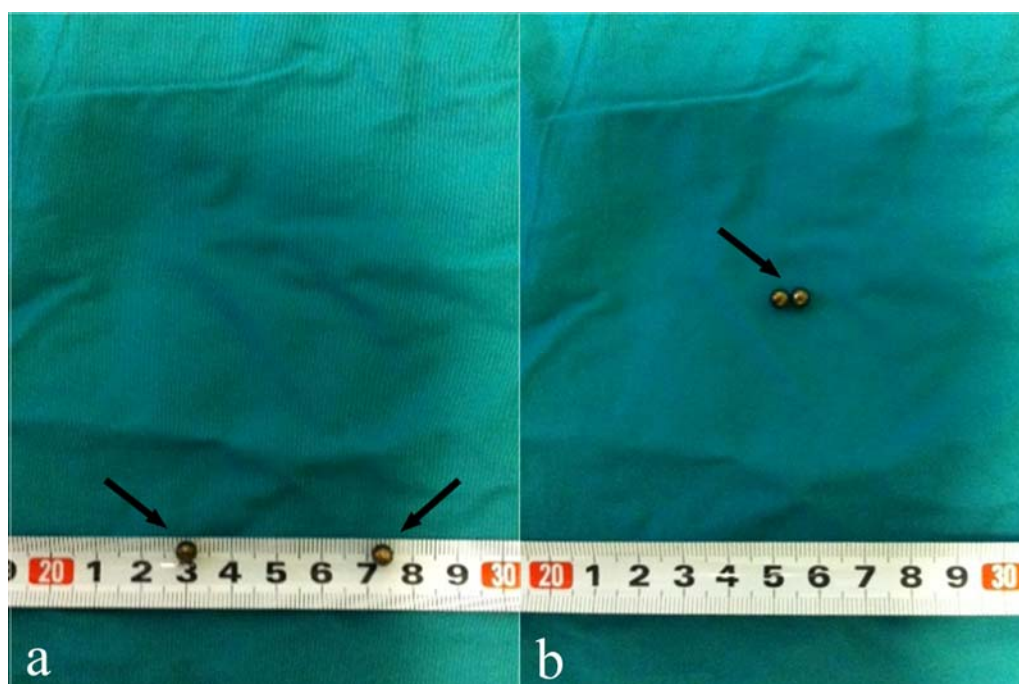


Fig. 3 – Photo of a foreign body: a) after it was removed from the intestinal loops [two small magnetic balls, 3 mm size (black arrow)]; b) two small magnetic balls are capable of attracting each other (black arrow).

Discussion

Only about 20% of ingested FB were observed in adults, while the remaining 80% of cases were reported in children⁸. Reviewing the available literature data from June 1987 to October 2010, out of 149 cases identified as magnet ingestion injuries, only 6 (4.02%) patients were ≥ 18 years and the oldest patient was 48 years^{3, 5, 9–11}. In 80% of cases, swallowed FB passed stomach, small intestine and colon without no complications¹². Swallowed FB that cause severe abdominal complications are usually sharp objects such as toothpicks, needles, chicken bones and fish bones^{13, 14}. Swallowed magnetic FB are especially interesting. If a patient swallows a single magnet it is usually harmless. Nevertheless over 50% of patients swallow two or more magnets⁶. The problem arises when a patient swallows two or more

magnets, one after the other, at certain intervals, which results in a strong mutual attraction of magnets through the wall of the hollow organs of the abdomen, and can cause intestinal wall ischemia, necrosis and perforation with peritonitis, or intestinal fistula formation^{1, 15–18}.

We reported a case of a young patient who swallowed 2 very small magnets, presented as acute bowel obstruction that required emergency surgery.

The presence of ingested magnets usually can be seen on radiography or abdominal ultrasound, but clinicians rarely think of swallowing magnets in adults^{4, 6}. On abdominal radiography with air-fluid levels, sometimes the metallic shadow of two magnets can be seen with a small free space between them, just in the place where they attached through the wall of the hollow organs⁶. These FB shadows do not change position on repeated radiography. In unclear clinical

cases who require additional diagnostic methods, swallowed magnetic FB may be disclosed on the abdominal ultrasound or abdominal CT¹⁶. If magnetic FB are highly suspected as a cause of abdominal complications the magnetic resonance imaging should be avoided^{6,16}. In our case, the patient was not aware that he had swallowed magnets; on abdominal we did not recognize that FB are magnets; so, finally, 2 small magnetic balls were discovered at surgery. Our patient probably swallowed two magnetic balls one by one at a certain time interval, therefore, there has been a magnet attracted by one in the jejunal loop and the other in the distal ileum loop causing small bowel obstruction due to the small bowel twisting around this point of rotation and intestinal fistula, which required urgent surgical treatment. If the magnets still remain in the esophagus or stomach, they must be urgently

removed endoscopically^{15,17}. In other cases the emergency explorative laparotomy should be performed because of the potential severe abdominal complication following magnets ingestion^{15,17}.

Conclusion

Swallowing magnets one by one at a certain time interval can lead to severe acute complications that require emergency surgery. Multiple magnets ingestion is expected rarely in adults, but if unrecognized, they could carry a significant risk of morbidity. Clinicians should always keep in mind a possibility of magnetic FB ingestion, especially when the etiology of the acute abdominal symptoms is unknown.

R E F E R E N C E S

1. *Gob BK, Chow PK, Quah H, Ong HS, Eu KW, Ooi LL, et al.* Perforation of the gastrointestinal tract secondary to ingestion of foreign bodies. *World J Surg* 2006; 30(3): 372–7.
2. *Ayantunde AA, Oke T.* A review of gastrointestinal foreign bodies. *Int J Clin Pract* 2006; 60(6): 735–9.
3. *Liu S, Li J, Lv Y.* Gastrointestinal damage caused by swallowing multiple magnets. *Front Med* 2012; 6(3): 280–7.
4. *Wildhaber BE, le Coultre C, Genin B.* Ingestion of magnets: innocent in solitude, harmful in groups. *J Pediatr Surg* 2005; 40(10): e33–5.
5. *Tay ET, Weinberg G, Levin TL.* Ingested magnets: the force within. *Pediatr Emerg Care* 2004; 20(7): 466–7.
6. *Lee JH, Kim HC, Yang DM, Kim SW, Jin W, Park SJ, et al.* What is the role of plain radiography in patients with foreign bodies in the gastrointestinal tract. *Clin Imag* 2012; 36(5): 447–54.
7. *Kircher MF, Milla S, Callaban MJ.* Ingestion of magnetic foreign bodies causing multiple bowel perforations. *Pediatr Radiol* 2007; 37(9): 933–6.
8. *Brown JC, Murray KF, Javid PJ.* Hidden attraction: A menacing meal of magnets and batteries. *J Emerg Med* 2012; 43(2): 266–9.
9. *Baliga SK, Hussain D, Sarfrax SL, Hartung RU.* Magnetic attraction: dual complications in a single case. *J Coll Physicians Surg Pak* 2008; 18(7): 440–1.
10. *Nisbi Y, Sasajima K, Matsutani T, Miyamoto M, Hiroshi MH, Yokoyama T, et al.* Intestinal fistulas caused by ingestion of magnets in an adult. *Jpn J Gastroenterol Surg* 2008; 41(12): 2069–74.
11. *Rashid F, Davies L, Iftikhar SY.* Magnetised intragastric foreign body collection and autism: An advice for carers and literature review. *Autism* 2010; 14(2): 139–45.
12. *Vijaysadam V, Perez M, Kuo D.* Revisiting Swallowed Troubles: Intestinal complications caused by two magnets - A case report, review and proposed revision to the algorithm for the management of foreign body ingestion. *J Am Board Fam Med* 2006; 19(5): 511–6.
13. *Bisharat M, O'Donnell ME, Gibson N, Mitchell M, Refsum SR, Carey PD, et al.* Foreign body ingestion in prisoners: The Belfast experience. *Ulster Med J* 2008; 77(2): 110–4.
14. *Doklestic KS, Karamarkovic AR.* Ileum perforation due to accidental chicken bone ingestion a rare cause of the acute abdomen. *Sanamed* 2012; 7(1): 31–4.
15. *Brown DJ.* Small bowel perforation caused by multiple magnet ingestion. *J Emerg Med* 2010; 39(4): 497–8.
16. *Gayer G, Petrovitch I, Jeffrey RB.* Foreign objects encountered in the abdominal cavity at CT. *Radiographics* 2011; 31(2): 409–28.
17. *Ilçe Z, Samsun H, Mammadov E, Celayir S.* Intestinal volvulus and perforation caused by multiple magnet ingestion: Report of a case. *Surg Today* 2007; 37(1): 50–2.
18. *Oh HK, Ha HK, Shin R, Ryoo SB, Choe EK, Park KJ.* Jejuno-jejunal fistula induced by magnetic necklace ingestion. *J Korean Surg Soc* 2012; 82(6): 394–6.

Received on February 14, 2016.

Revised on March 27, 2016.

Accepted on April 11, 2016.

Online First October, 2016.