



## The efficacy of moxifloxacin in patients with bacterial keratitis

### Efikasnost primene moksifloksacina kod bolesnika sa bakterijskim keratitisom

Katarina M. Janićijević\*, Sanja Kocić\*, Snežana Radovanović\*,  
Svetlana Radević\*, Olgica Mihailjević\*, Mirjana Janićijević Petrović\*†

University of Kragujevac, \*Faculty of Medical Sciences, Kragujevac, Serbia; Clinical  
Centre of Kragujevac, †Clinic of Ophthalmology, Kragujevac, Serbia

#### Abstract

**Background/Aim.** Keratitis is a sociomedical problem of moderately developed countries, including Serbia, too. The incidence of bacterial keratitis in the world is about 20% in relation to all keratitis, but its frequency in Serbia is still not known. Bearing in mind the complications in the front segment of the eye after bacterial keratitis (ulcer, neovascularization, fibrosis) and decline in visual acuity, it was necessary to assess the efficacy of local therapy by moxifloxacin which will shorten the healing time and reduce complications. The aim of the study was to analyze the efficiency of shortening the treatment of bacterial keratitis with moxifloxacin. **Methods.** The study was designed as prospective, randomized, double-blind study. The study included 30 patients with diagnosed keratitis and locally applied antibiotic moxifloxacin, and 60 patients in a control group, with locally applied artificial tears. All participants were subjected to complete clinical ophthalmologic analysis (2015/16), for a period of 1–15 days after the application of therapies (healing time of corneal pathology). The following was determined in all patients: degree of hyperemia, degree of epithelial defect, level of corneal sensitivity, level of tear secretion and tear quality, degree of conjunctival secretion, degree of neovascularisation and corneal scarring, degree of visual acuity, score of subjective symptomatology and correlation of ophthalmological findings and subjective symptoms. **Results.** There was a statistically significant difference in times of therapeutic efficacy/clinical response between the study group patients who received moxifloxacin and the control group patients who received artificial tears. **Conclusion.** Local application of moxifloxacin had therapeutic effect (total benefit) both in terms of the effective shortening of the healing time and also the reduction of the complications of bacterial keratitis, without unwanted effects.

#### Key words:

keratitis; moxifloxacin; bacterial infections; treatment outcome.

#### Apstrakt

**Uvod/Cilj.** Keratitis su sociomedicinski problem srednje razvijenih zemalja u koje spada i Srbija. U odnosu na sve keratitise, učestalost bakterijskih keratitisa u svetu je oko 20%, a u Srbiji je još nepoznate učestalosti. Imajući u vidu komplikacije na prednjem segmentu oka nakon bakterijskog keratitisa (ulkus, neovaskularizacija, fibroza) i pad oštine vida, bilo je potrebno proceniti efikasnost lokalne terapije moksifloksacinom, koja će skratiti vreme izlečenja i redukovati komplikacije. Cilj rada bio je analiza efikasnosti lečenja bakterijskih keratitisa moksifloksacinom. **Metode.** Studija je osmišljena kao prospektivna, randomizovana, dvostruko slepa klinička studija. Ona je obuhvatila 30 bolesnika sa dijagnostikovanim keratitisom i lokalno aplikovanim antibiotikom moksifloksacinom i 60 ispitanika kontrolne grupe, sa lokalno aplikovanim veštačkim suzama. Ispitanici su podvrgnuti kompletnoj oftalmološkoj analizi tokom 2015/16. godine u planiranom periodu od 1. do 15. dana od primene terapija (vreme sanacije kornealne patologije). Kod svih ispitanika određivan je stepen hiperemije, težina kornealnog defekta, kornealni senzitivitet, količina suza i kvalitet suznog filma, konjunktivalna sekrecija, neovaskularizacija i ožiljne formacije rožnjače, funkcionalna oština vida, skor subjektivne simptomatologije i korelacije oftalmološkog kliničkog nalaza i subjektivnih simptoma. **Rezultati.** Utvrđena je statistički značajna razlika u pogledu terapijske efikasnosti/kliničkog odgovora između studijske grupe, koja je primala moksifloksacin i kontrolne grupe, koja je primala placebo. **Zaključak.** Lokalna primena moksifloksacina je ostvarila terapijsku efektivnost (ukupan terapijski benefit), kako u domenu efikasnog skraćivanja vremena izlečenja, tako i u redukciji komplikacija keratitisa, bez neželjenih dejstava.

#### Ključne reči:

keratitis; moksifloksacin; infekcija, bakterijska; lečenje, ishod.

## Introduction

Keratitis is an acute or chronic inflammation of the cornea which is medically significant, clinically clearly rated as sufficiently specific and important in diagnosis and therapy. The incidence of bacterial keratitis in the world is about 20% in relation to all keratitis<sup>1</sup>. Bacterial keratitis, after the herpetic keratitis transactions, is most common in the developed world [30,000 cases per year in the USA (8 : 100,000)]<sup>2, 3</sup>. Frequency of incidence in Serbia is still unknown.

The clinical picture of bacterial keratitis is characterized by relatively non-specific symptoms<sup>1</sup>.

Bacterial keratitis is characterized by generally good clinical prognosis and often is monocular<sup>4</sup>. With regard to innervation the cornea is one of the most sensitive tissues, innervated by the sensitive nerves. Epithelization of cornea defect shows not only control "eye score", but also neurotrophic rehabilitation in patients with bacterial keratitis/ulcer<sup>4, 5</sup>.

Moxifloxacin is an antibiotic belonging to the 4th generation of fluoroquinolones and an antibacterial agent in the local treatment of bacterial keratitis and/or conjunctivitis. It covers a spectrum of gram positive, gram negative, anaerobic and atypical microorganisms inhibiting topoisomerase II - DNA gyrase and topoisomerase-IV. Both enzymes are necessary for DNA replication, repair and recombination of bacterial microorganisms<sup>6</sup>.

Moxifloxacin has excellent penetration through the cornea and conjunctiva, destroys pathogens quickly and efficiently, and it is characterized by low level of development of potential adverse effects as well as by low level of resistance. It is well tolerated clinically when applied locally and its effect is parallel to "ocular discomfort", caused by application of artificial tears, or placebo<sup>6-9</sup>.

The aim of this study was to investigate whether the local application of moxifloxacin in patients with bacterial keratitis can effectively accelerate corneal epithelialization, or soft cure with a reduction of complications, in comparison with local placebo treatment (artificial tears).

## Methods

The study was designed as a prospective, randomized, double-blind, clinical study. The study involved patients with acute bacterial keratitis diagnosed according to clinical protocols in the period 2015/16, and treated at the Clinic of Ophthalmology in the Clinical Center "Kragujevac", Kragujevac, Serbia. The study group included 30 hospitalized patients, aged 7-70 years (average age  $44.2 \pm 15.8$  years). The control group included twice as many respondents, 60 of them (average age  $40.8 \pm 13.6$  years) with bacterial keratitis, treated with topical application of artificial tears (hydroxypropyl methylcellulose). Out of the total number of respondents in the study group, there were 17 (56.7%) females and 13 (43.3%) males. In the control group there were 29 (48.3%) females and 31 (51.7%) males. The respondents were subjected to a study of control/analysis with a daily control pattern from 1 to 15 days (the visit/rounds on 8-10 h) after application of the local therapies. Epithelialization de-

fect of cornea showed neuro-quality of sensation to touch-pain, a threshold of tactile sensitivity and dynamics of the recovery of corneal innervation (estenziometar by Cochet-Bonnet). Length was gradually decreased until the first reactions of patients, avoided spontaneous blinking and/or subjectivity. Sensitivity decreases from the center to the upper-temporal, nasal and lower regions (a phenomenon of "failure sensitivity" and the existence of bilateral asymmetry, depending on pathological changes and/or approximation of pathological values)<sup>10</sup>.

We analyzed the intensity of fluorescein (Fl)-staining defects of the cornea (epithelium/stroma, larger lesions, equal or smaller than 2 mm, of the slit-lamp (evolution of keratitis in ulcer) with standardized gradation: Fl +++, Fl ++, Fl +, Fl -<sup>11-19</sup>.

Schirmer's test-1 (without local anesthesia), was used for estimating amount of tears („soaked paper" less, normal 10 mm/5 min, or more), and break-up time of tear film [tear break-up time (TBUT)] test, which determined the required quality of tear film (destabilization/stabilization of film), and appearance of the first cracks in tear film (time: less, normally for 10 sec, or more)<sup>20-22</sup>.

The presence/absence and occurrence/evolution of the eye-hyperemia (conjunctival, ciliary, mixed), presence/absence of macro-characteristics and degree of conjunctival secretion, the presence/absence and type of pannus (superficial, deep, mixed), presence/absence, type and degree of scar-formation (nubecula, macula, leucom) were analyzed on the slit-lamp<sup>23-25</sup>. We analyzed the visual acuity (Snellen optotype) from causal minus (fall), through the normal/unchanged, until normal/enhanced (increased) functional visual acuity (with and/or without correction).

Analyses of subjective symptoms with elimination of pain/burning, foreign body sensation and reduction of epiphora, blepharospasm and photophobia (trias irritative symptoms), i.e. discomfort (answers to questions from the authentic questionnaires with the score-system: 0 - no, 1 - discreetly, 2 - expressed, 3 - intense) were done<sup>26-28</sup>.

On the basis of composite to monocular clinical findings/analysis in controls by day, bacterial keratitis was categorized as cured or uncured (dihotona binary variable), and the final outcome was assessed 15 days after the beginning of the local therapy with moxifloxacin or artificial tears, as healed or not healed (progressive phase of active lesions, regression and healing). All parameters were analyzed before starting drug application, or artificial tears as well as 3, 6, 9, 12 and 15 days from the beginning of treatments.

To calculate the sample size, the software package G-Power 3.1.7. was used - studies on power ( $1-\beta$ ) = 0.8,  $\alpha$  = 0.05 for the Student's *t*-test. For statistical analysis authors used SPSS (Statistical Package Social Sciences) program 18.0 for Windows. The differences of parameters through the study period of 15 days were analyzed by the Friedman's test, and the differences between the study and control group of patients were analyzed by the Mann Whitney test. The correlation between some variables were tested by bivariate correlation test, Pearson's and Spearman's coefficients.

Procedure of the study was conducted in accordance with the ethical standards of Committee for Experiments on

Humans (Helsinki Declaration) and with consent of the competent Ethic Committee in the Clinical Center „Kragujevac“.

## Results

The study analyzed the degree of hyperemia determined as mild, moderate or severe hyperemia. Before the therapy in the study group 7 (23.3%) patients had mild hyperemia, 11 (36.7%) patients had moderate and 12 (40%) patients had severe hyperemia. In the control group, 15 (25%) patients had mild, 18 (30%) patients had moderate and 27 (45%) patients had severe hyperemia. There was a statistically significant reduction in the degree of hyperemia in the group of patients treated with the antibiotic during the observation period of 15 days ( $p < 0.001$ ). In contrast, it was shown that there was a statistically significant increase in the degree of hyperemia in the control group ( $p < 0.001$ ).

Using mutual comparison of the values of hyperemia in the study and control group a significant progressive decrease in the degree of hyperemia in the study group, and an increase in hyperemia in the control group starting from the 6th day ( $p < 0.001$ ) were found (Table 1).

The study also analyzed the degree of damage of the cornea, determined as mild ( $< 2$  mm), moderate (2 mm) and severe defects ( $> 2$  mm). In the study group, 8 (26.7%) patients had mild degree of corneal damage, 7 (23.3%) patients had moderate and 15 (50%) patients had high degree of damage of the cornea. In the control group, 17 (28.3%) patients had mild degree of corneal damage, 17 (28.3%) patients had moderate and 26 (43.3%) patients had high degree of corneal damage. There was a statistically significant reduction in the degree of the cornea damage in the study group ( $p < 0.001$ ). In contrast, it was shown that there is a statistically significant increase in the degree of corneal damage in the control group of patients ( $p < 0.001$ ). Using mutual comparison of the corneal defect degree in the study group and control group it was found that 3 days after the treatment, there was statistically significant difference in the severity of defects between these two groups of patients starting from the 6th day ( $p < 0.001$ ) (Table 1).

The degree of sensitivity preservation was represented as anesthesia, hypoesthesia and maintained sensitivity. Before the treatment in the study group, 2 (6.7%) patients had anesthesia, 3 (10%) patients had hypoesthesia, and 15 (83.3%) patients had maintained sensitivity. In the control group of patients, 2 (3.3%) patients had anesthesia, 5 (8.3%) patients had hypoesthesia, and 53 (88.4%) patients had maintained sensitivity. By processing the obtained data, there was found a statistically significant increase in the degree of sensitivity preservation in the study group of patients ( $p < 0.001$ ). In contrast, statistically significant reduction was shown in the degree of preservation of sensitivity in the control group ( $p < 0.001$ ). Fall of corneal sensitivity had a progressive character.

Using mutual comparison of the value of sensitivity preservation in the study and control group the significant differences was found throughout all study period ( $p < 0.001$ ) (Table 1).

The degree of tear secretion was analyzed by Schirmer-test, and the results displayed as reduced amount of tears, a normal amount of tears and increased amount of tears. Before the use of the antibiotic in the study group, 3 (10%) patients had a reduced amount of tears, 9 (30%) patients had normal and 18 (60%) patients had increased amount of tears. In the control group, 3 (5%) patients had reduced amount of tears, 26 (43.3%) patients had normal and 31 (51.7%) patients had increased amount of tears. Processing the obtained data, there was statistically significant reduction in the amount of tears in the study group ( $p < 0.001$ ). In contrast, it was shown that there was a statistically significant increase in the secretion of tears in the control group ( $p < 0.001$ ). Using mutual comparison of the value of the quantity of tears it was found a statistically significant difference in the secretion of tears between the two groups ( $p = 0.009$ ) (Table 1).

The quality of the tear film (TBUT test) was analyzed and classified as bad quality, poor quality and good quality. Before the use of the antibiotic in the study group, 8 (26.7%) patients had bad quality, 20 (66.7%) patients had poor quality and 2 (6.6%) patients had good quality of the tear film. In the control group of patients prior to the treatment, 16 (26.7%) patients had bad quality, 35 (58.3%) patients had poor quality and 9 (15%) patients had good quality of the tear film. By processing the data obtained it was found a statistically significant improvement in the quality of tear film in the study group ( $p < 0.001$ ). It was shown a statistically significant reduction in the quality of the tear film in the control group ( $p < 0.001$ ). Using mutual comparison of the quality of the tear film between the two groups of patients statistically significant difference was found starting from the 3rd day of the treatment ( $p = 0.033$ ) (Table 1).

The degree of conjunctival secretion was determined as poor, moderate and abundant secretion. Before the use of the antibiotic in the study group, 2 (6.7%) patients had no conjunctival secretion, 8 (26.7%) patients had scant secretion, 15 (50%) patients had moderate and 5 (16.6%) patients abundant secretion. In the control group, 5 (8.3%) patients had no secretion, 19 (31.6%) patients had meager secretion, 10 (16.7%) patients had moderate and 26 (43.4%) patients had abundant secretion. By processing the data obtained a statistically significant reduction in the degree of conjunctival secretion was found in the group of patients treated with the antibiotic ( $p < 0.001$ ). In contrast, a statistically significant increase in the degree of conjunctival secretion was shown in patients treated with artificial tears ( $p < 0.001$ ). Mutual comparison of the value of conjunctival secretion showed the significant differences in the severity of conjunctival secretion between the two groups of patients starting from the 3rd day of the treatment ( $p = 0.012$ ) (Table 1).

The study analyzed the presence or absence, and the degree of corneal neovascularization (determined as surface, deep and mixed). Before the use of antibiotics in the study group, 10 (33.3%), patients were without elements of neovascularization, 14 (46.7%) patients had surface, 4 (13.3%) patients had deep and 2 (6.7%) patients had mixed corneal neovascularization. In the control group, 22 (36.7%) patients had no neovascularization, 30 (50%) patients had superficial,

**Table 1**

**Changes of the analyzed parameters (clinical and prognostic factors) in the study group of subjects during the period of 15 days**

Parameter	Days					
	1	3	6	9	12	15
Hyperemia, degree						
study group	2.01 ± 0.63	1.88 ± 0.63	1.38 ± 0.50	0.72 ± 0.49	0.45 ± 0.42	0.32 ± 0.53
control group	1.95 ± 0.88	1.93 ± 0.67	1.80 ± 0.66	2.21 ± 0.77	2.41 ± 0.55	2.66 ± 0.61
Corneal defect, degree						
study group	2.05 ± 0.82	1.94 ± 0.78	1.44 ± 0.52	0.56 ± 0.47	0.28 ± 0.55	0.17 ± 0.44
control group	1.97 ± 0.83	1.98 ± 0.63	1.98 ± 0.63	2.30 ± 0.71	2.44 ± 0.66	2.29 ± 0.79
Preservation of corneal sensitivity, degree						
study group	2.96 ± 0.3	2.94 ± 0.10	2.98 ± 0.15	2.90 ± 0.25	2.74 ± 0.44	3.02 ± 0.19
control group	2.99 ± 0.40	2.5 ± 0.57	2.42 ± 0.58	2.39 ± 0.61	2.32 ± 0.54	2.1 ± 0.60
Tears secretion (Schirmer test), mm						
study group	2.45 ± 0.64	2.10 ± 0.34	1.89 ± 0.19	1.80 ± 0.43	1.78 ± 0.30	1.72 ± 0.27
control group	2.42 ± 0.51	2.30 ± 0.39	2.40 ± 0.58	2.61 ± 0.56	2.68 ± 0.57	2.78 ± 0.44
Quality of tear film (tBUT test), sec						
study group	1.78 ± 0.45	2.18 ± 0.39	2.37 ± 0.62	2.70 ± 0.41	2.85 ± 0.33	2.98 ± 0.31
control group	1.80 ± 0.59	1.76 ± 0.47	1.43 ± 0.51	1.38 ± 0.55	1.24 ± 0.49	1.19 ± 0.41
Conjunctival secretion, degree						
study group	2.10 ± 0.42	1.72 ± 0.77	1.25 ± 0.68	0.90 ± 0.54	0.43 ± 0.56	0.31 ± 0.32
control group	1.99 ± 0.44	2.35 ± 0.53	2.42 ± 0.61	2.54 ± 0.48	2.68 ± 0.71	2.75 ± 0.37
Neovascularisation of cornea, degree						
study group	0.77 ± 0.67	0.50 ± 0.63	0.36 ± 0.55	0.24 ± 0.49	0.15 ± 0.5	0.1 ± 0.48
control group	0.81 ± 0.62	0.99 ± 0.69	1.21 ± 0.88	1.68 ± 0.56	2.02 ± 0.33	2.18 ± 0.74
Scar complications of cornea, degree						
study group	0.64 ± 0.68	0.60 ± 0.51	0.39 ± 0.47	0.28 ± 0.53	0.20 ± 0.52	0.13 ± 0.33
control group	0.62 ± 0.52	0.79 ± 0.76	1.20 ± 0.53	1.64 ± 0.66	2.10 ± 0.82	2.19 ± 0.89
Functional visual activity, degree						
study group	1.35 ± 0.41	1.75 ± 0.59	2.08 ± 0.66	2.28 ± 0.36	2.73 ± 0.47	2.94 ± 0.46
control group	1.56 ± 0.55	1.52 ± 0.41	1.24 ± 0.48	1.20 ± 0.48	1.17 ± 0.34	1.10 ± 0.37

**tBUT – tear breakup time.**

5 (8.3%) patients had deep and 3 (5%) patients had mixed neovascularization. After processing the obtained data it was found that there was a statistically significant reduction in the degree of neovascularization in the group of patients treated with the antibiotic ( $p < 0.001$ ). In contrast, it was shown a statistically significant increase in the degree of neovascularization in patients treated with artificial tears ( $p < 0.001$ ). Using mutual comparison of the corneal neovascularization values in the study and the control group, significant differences were found in the severity of these complications between the two groups of patients starting from the 3rd day of the treatment ( $p = 0.025$ ) (Table 1).

The study analyzed the presence or absence (0) scar formations and change (determined as nubecula, macula and leucom). Before the use of the antibiotic in the study group, 15 (50%) of patients had no scars change, 11 (36.7%) patients had nubecula, 3 (10%) patients had macula, and 1 (3.3%) patient had leucom. In the control group, 35 (58.3%) patients were without scars change, 19 (31.6%) patients had nubecula, 3 (5%) patients had macula and 3 (5.1%) patients had leucom. By processing the obtained data a statistically

significant severity reduction in scars changes was found in the group of patients treated with the antibiotic ( $p < 0.001$ ). In contrast, a statistically significant increase in severity of scar changes was shown in the control group ( $p < 0.001$ ). Using mutual comparison of scars weight changes severity in the study and control group, a significant difference between them was found in prevalence of scar changes starting from the 3rd day of the study period ( $p = 0.029$ ) (Table 1).

We studied the functional visual acuity (determined as poor/reduced from 0.01–0.1, less 0.2–0.5 and good/improved 0.6–1.0). Before the use of the antibiotic in the study group, 23 (76.7%) patients had poor visual acuity, 6 (20%) patients had lower and 1 (3.3%) patient had good visual acuity. In the control group of patients, 31 (51.7%) patients had poor visual acuity, 24 (40%) patients had lower and 5 (8.3%) patients had good visual acuity. By processing the obtained data there was a statistically significant improvement found in visual acuity in patients treated with the antibiotic ( $p < 0.001$ ). There was a statistically significant decrease in functional visual acuity found in patients treated with artificial tears ( $p < 0.001$ ). Using mutual comparison of visual acuity in the

study group and the control group, a statistically significant difference was found in the functional visual acuity between the two groups of patients ( $p < 0.001$ ) (Table 1).

The study analyzed the subjective symptomatology testing the presence of the pain/tingling feeling (0-absent/none, 1-discreet, 2-expressed, 3-intensive), the presence of foreign body feeling (0-absent/none, 1-discreet, 2-expressed, 3-intensive) and the presence of irritative trias (blepharospasm, epiphora, photophobia: 0-absent/none, 1-discreet, 2-expressed, 3-intensive). The results were then interpreted in relation to the score of subjective symptoms (0-9). Scores were analyzed before and after the therapy. Statistically significant reduction in the severity of subjective symptoms was found 15 days after the antibiotic treatment ( $p < 0.001$ ). The average value score before administration of the antibiotics was  $7.7 \pm 0.73$  and after the therapy  $1.66 \pm 0.82$ . In contrast, in the control group there was no statistically significant changes in subjective symptoms after application of artificial tears ( $7.52 \pm 1.07$  vs.  $7.37 \pm 0.59$ ) ( $p = 0.357$ ). Using mutual comparison of the scores in the study and control group, significant differences in the severity of subjective symptoms were found ( $p < 0.001$ ) (Figure 1).

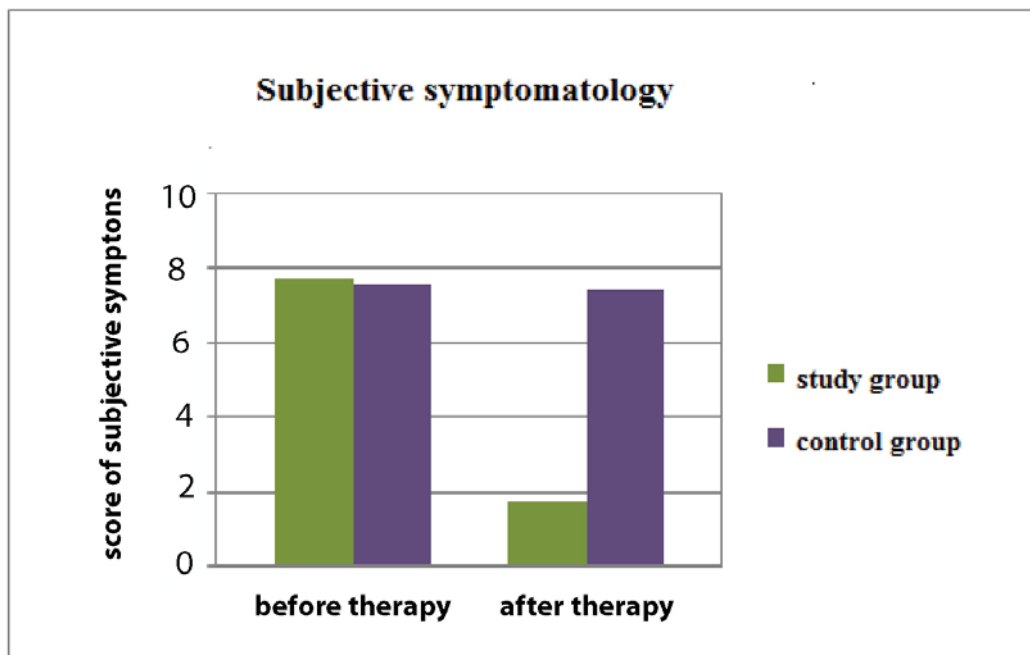
jective symptoms score differences before and after the treatment and the degree of hyperemia ( $r = 0.155$ ,  $p = 0.180$ ), the degree of corneal defect ( $r = 0.181$ ,  $p = 0.243$ ), and the severity of conjunctival secretion ( $r = 0.490$ ,  $p = 0.069$ ).

### Discussion

Modern clinical studies confirm that the 4th generation of fluoroquinolones have advantage over the previous generations against gram positive bacteria<sup>29</sup>. For example, moxifloxacin compared with non-fluoroquinolones antibiotics “kills” faster *Staphylococcus aureus*, *Streptococcus pneumoniae* and *Haemophilus influenzae*<sup>30</sup>.

The leading multicenter studies use moxifloxacin as fast and effective treatment of bacterial keratitis/ulcer, as we used in our study<sup>31-33</sup>.

Many studies suggest different procedures available for purchase, the regime of antibiotic applications and different concentrations of pharmacological preparations for remediation of bacterial inflammation - keratitis<sup>39,40</sup>. Respecting the principles of good clinical practice in the treatment of bacterial keratoconjunctivitis, there is a need to find new and/or



**Fig. 1 – Subjective eye-symptoms (score) in the study and control group before and after therapy. (Study group – treated with local application of moxifloxacin; Control group – treated with arteficial tears).**

We also analyzed the relation between the objective ophthalmologic findings and subjective symptoms. There was a statistically significant correlation between differences of the subjective symptoms score before and after the treatment and the degree of corneal sensitivity ( $r = 0.365$ ,  $p = 0.038$ ), the level of secretion of tears ( $r = 0.510$ ,  $p = 0.042$ ), the quality of the tear film ( $r = 0.587$ ,  $p = 0.037$ ), the degree of neovascularization ( $r = 0.916$ ,  $p = 0.009$ ), the level of scars complications ( $r = 0.688$ ,  $p = 0.033$ ), the degree of preservation of functional visual acuity ( $r = 0.748$ ,  $p = 0.025$ ). There was no statistically significant correlation between su-

alternative therapies which should bring overall benefits than current therapeutic options could do, including part-time as local steroid and/or combination of treatments<sup>34, 35</sup>. In our study we did not have any needs to use a cortisteroid for the treatment. It is encouraging to note that the early effects achieved with moxifloxacin “*in vitro/in vivo*” are therapeutic solution which shortens the time for healing treatment of bacterial keratitis, keratoconjunctivitis, and corneal ulcers<sup>36-39</sup>. Clinical studies now suggest different methods of application of moxifloxacin (e.g. subconjunctival injections) in patients with severe clinical forms of bacterial keratitis/ulcer<sup>40</sup>, which was

not indicated for any of our patients. On the other hand, a certain pharmacological effects of fluoroquinolones on nervous tissue which belongs to moxifloxacin, could compromise the expected benefit in the treatment of the corneal inflammation. Recently it has been discovered that moxifloxacin inhibits fibroblast to myofibroblast differentiation, i.e. produces anti-fibrotic effect improving corneal wound healing<sup>41</sup>.

Fluoroquinolones have an improved bactericidal effect against gram positive microorganisms, and reduced risk of phototoxicity and adverse events in relation to the previous quinolone generations<sup>42-44</sup>. Moxifloxacin resistance deve-

lops slowly<sup>45</sup>. Its adverse reactions were generally mild, at rate similar to placebo (artificial tears) (transient ocular discomfort – mild discomfort of 2.9%)<sup>43,44,46</sup>.

### Conclusion

Moxifloxacin had significant therapeutic effect (total benefit) both in terms of the effective shortening time of healing (epithelization corneal defects real fast) and reduction of complications of bacterial keratitis, without unwanted effects.

### R E F E R E N C E S

1. *Al-Mujaini A, Al-Kharusi N, Wali UK*. Bacterial Keratitis: Perspective on Epidemiology, Clinic-Pathogenesis, Diagnosis and Treatment. *Sultan Qaboos Univ Med J* 2009; 9(2): 184–95.
2. *Chikviladze D, Nikuradze N, Gachechiladze K, Migeladze M, Mtreveli D*. Microbial structure of acute bacterial conjunctivitis. *Georgian Med News* 2013; 216: 12–5. (Russian)
3. *Green M, Apel A, Stapleton F*. Risk factors and causative organisms in microbial keratitis. *Cornea* 2008; 27(1): 22–7.
4. *Schaefer F, Bruttin O, Zografos L, Gnex-Crosier Y*. Bacterial keratitis: A prospective clinical and microbiological study. *Br J Ophthalmol* 2001; 85(7): 842–7.
5. *Vajpayee RB, Dada T, Saxena R, Vajpayee M, Taylor HR, Venkatesh P*, et al. Study of the first contact management profile of cases of infectious keratitis: A hospital-based study. *Cornea* 2000; 19(1): 52–6.
6. *Pawar P, Katara R, Mishra S, Majumdar DK*. Topical ocular delivery of fluoroquinolones. *Expert Opin Drug Deliv* 2013; 10(5): 691–711.
7. *Vignesh AP, Srinivasan R, Karanth S*. A Case Report of Severe Corneal Toxicity following 0.5% Topical Moxifloxacin Use. *Case Rep Ophthalmol* 2015; 6(1): 63–5.
8. *Benitez-del-Castillo J, Verboren Y, Stroman D, Kodjikian L*. The role of topical moxifloxacin, a new antibacterial in Europe, in the treatment of bacterial conjunctivitis. *Clin Drug Investig* 2011; 31(8): 543–57.
9. *Schleeb BA, Alfonso E*. Overview of the potency of moxifloxacin ophthalmic solution O. 5% (VIGAMOX). *Surv Ophthalmol* 2005; 50(Suppl 1): S7–15.
10. *Labbe A, Liang Q, Wang Z, Zhang Y, Xu L, Baudouin C*, et al. Corneal nerve structure and function in patients with non-sjogren dry eye: Clinical correlations. *Invest Ophthalmol Vis Sci* 2013; 54(8): 5144–50.
11. *Toker E, Asfuroglu E*. Corneal and conjunctival sensitivity in patients with dry eye: The effect of topical cyclosporine therapy. *Cornea* 2010; 29(2): 133–40.
12. *Moore PA*. Diagnosis and management of chronic corneal epithelial defects (indolent corneal ulcerations). *Clin Tech Small Anim Pract* 2003; 18(3): 168–77.
13. *Goldberg HL*. Clinical assessment, diagnosis, and management of the cornea. *Can Fam Physician* 1990; 36(4): 741–3.
14. *Kikkawa Y*. Normal corneal staining with fluorescein. *Exp Eye Res* 1972; 14(1): 13–20.
15. *Bandamwar KL, Papas EB, Garrett Q*. Fluorescein staining and physiological state of corneal epithelial cells. *Cont Lens Anterior Eye* 2014; 37(3): 213–23.
16. *Ward KW*. Superficial punctate fluorescein staining of the ocular surface. *Optom Vis Sci* 2008; 85(1): 8–16.
17. *Feenstra RP, Tseng SC*. Comparison of fluorescein and rose bengal staining. *Ophthalmology* 1992; 99(4): 605–17.
18. *Wilson G, Ren H, Laurent J*. Corneal epithelial fluorescein staining. *J Am Optom Assoc* 1995; 66(7): 435–41.
19. *Miyata K, Amano S, Sawa M, Nishida T*. A novel grading method for superficial punctate keratopathy magnitude and its correlation with corneal epithelial permeability. *Arch Ophthalmol* 2003; 121(11): 1537–9.
20. *Himebaugh NL, Nam J, Bradley A, Liu H, Thibos LN, Begley CG*. Scale and spatial distribution of optical aberrations associated with tear break-up. *Optom Vis Sci* 2012; 89(11): 1590–600.
21. *Begley CG, Himebaugh N, Renner D, Liu H, Chalmers RL, Simpson T*, et al. Tear breakup dynamics: A technique for quantifying tear film instability. *Optom Vis Sci* 2006; 83(1): 15–21.
22. *Romanchuk KG*. Enhanced models for teaching slit-lamp skills. *Can J Ophthalmol* 2003; 38(6): 507–11.
23. *Cutler TJ*. Corneal epithelial disease. *Vet Clin North Am Equine Pract* 2004; 20(2): 319–43, vi.
24. *Himebaugh NL, Begley CG, Bradley A, Wilkinson JA*. Blinking and tear break-up during four visual tasks. *Optom Vis Sci* 2009; 86(2): E106–14.
25. *Macri A, Pflugfelder S*. Correlation of the Schirmer 1 and fluorescein clearance tests with the severity of corneal epithelial and eyelid disease. *Arch Ophthalmol* 2000; 118(12): 1632–8.
26. *Pflugfelder SC, Tseng SC, Sanabria O, Kell H, Garcia CG, Felix C*, et al. Evaluation of subjective assessments and objective diagnostic tests for diagnosing tear-film disorders known to cause ocular irritation. *Cornea* 1998; 17(1): 38–56.
27. *Mapstone R*. Anterior segment ischaemia and hyperaemia. *Trans Ophthalmol Soc U K* 1970; 90: 329–35.
28. *Blagojevic M*. Importance of conjunctival and ciliary hyperemia in diagnosis of eye diseases. *Med Glas* 1958; 12(1): 3–6. (Serbian)
29. *Fintelmann RE, Hoskins EN, Lietman TM, Keenan JD, Gaynor BD, Cevallos V*, et al. Topical fluoroquinolone use as a risk factor for in vitro fluoroquinolone resistance in ocular cultures. *Arch Ophthalmol* 2011; 129(4): 399–402.
30. *Lalitha P, Srinivasan M, Manikandan P, Bharathi MJ, Rajaraman R, Ravindran M*, et al. Relationship of in vitro susceptibility to moxifloxacin and in vivo clinical outcome in bacterial keratitis. *Clin Infect Dis* 2012; 54(10): 1381–7.
31. *Sueke H, Kaye S, Neal T, Murphy C, Hall A, Whittaker D*, et al. Minimum inhibitory concentrations of standard and novel antimicrobials for isolates from bacterial keratitis. *Invest Ophthalmol Vis Sci* 2010; 51(5): 2519–24.
32. *Callegan MC, Novosad BD, Ramadan RT, Wiskeur B, Moyer AL*. Rate of bacterial eradication by ophthalmic solutions of fourth-generation fluoroquinolones. *Adv Ther* 2009; 26(4): 447–54.
33. *Chung JL, Lim EH, Song SW, Kim BY, Lee JH, Mab FS*, et al. Comparative intraocular penetration of 4 fluoroquinolones after topical instillation. *Cornea* 2013; 32(7): 1046–51.

34. Wong CA, Galvis V, Tello A, Villareal D, Rey JJ. In vitro antibiotic susceptibility to fluoroquinolones. *Arch Soc Esp Oftalmol* 2012; 87(3): 72–8.
35. Williams L, Malhotra Y, Murante B, Laverty S, Cook S, Topa D, et al. A single-blinded randomized clinical trial comparing polymyxin B-trimethoprim and moxifloxacin for treatment of acute conjunctivitis in children. *J Pediatr* 2013; 162(4): 857–61.
36. Steger B, Speicher L, Philipp W, Gasser T, Schmid E, Bechrakis N. Effectiveness of initial antibiotic therapy for treatment of contact lens-related bacterial keratitis. *Ophthalmologie* 2014; 111(7): 644–8. (German)
37. Blanco C, Núñez MX. Antibiotic susceptibility of staphylococci isolates from patients with chronic conjunctivitis: Including associated factors and clinical evaluation. *J Ocul Pharmacol Ther* 2013; 29(9): 803–8.
38. Shib CY, Bosjolie A, Qiao M, Udell IJ. Bilateral corneal ulceration in keratoconus. *Ophthalmology* 2012; 119(10): 2192–2192.e3.
39. Borkekar DS, Fleiszgig SM, Leong C, Lalitha P, Srinivasan M, Ghaneekar AA, et al. Association between cytotoxic and invasive *Pseudomonas aeruginosa* and clinical outcomes in bacterial keratitis. *JAMA Ophthalmol* 2013; 131(2): 147–53.
40. Oldenburg CE, Lalitha P, Srinivasan M, Manikandan P, Bharathi MJ, Rajaraman R, et al. Moxifloxacin susceptibility mediates the relationship between causative organism and clinical outcome in bacterial keratitis. *Invest Ophthalmol Vis Sci* 2013; 54(2): 1522–6.
41. Mabvan TD, Hornecker JR, Buckley WA, Clark S. The role of besifloxacin in the treatment of bacterial conjunctivitis. *Ann Pharmacother* 2014; 48(5): 616–25.
42. Tauber S, Cupp G, Garber R, Bartell J, Vobra F, Stroman D. Microbiological efficacy of a new ophthalmic formulation of moxifloxacin dosed twice-daily for bacterial conjunctivitis. *Adv Ther* 2011; 28(7): 566–74.
43. Srinivasan M, Mascarenhas J, Rajaraman R, Ravindran M, Lalitha P, O'Brien KS, et al. The steroids for corneal ulcers trial (SCUT): Secondary 12-month clinical outcomes of a randomized controlled trial. *Am J Ophthalmol* 2014; 157(2): 327–33.e3.
44. Constantinou M, Daniell M, Snibson GR, Vu HT, Taylor HR. Clinical efficacy of moxifloxacin in the treatment of bacterial keratitis: A randomized clinical trial. *Ophthalmology* 2007; 114(9): 1622–9.
45. Park J, Lee KM, Zhou H, Rabin M, Jwo K, Burton WB, et al. Community practice patterns for bacterial corneal ulcer evaluation and treatment. *Eye Contact Lens* 2015; 41(1): 12–8.
46. Sharma C, Velpandian T, Baskar SS, Ranjan BN, Bibari VR, Ghose S. Effect of fluoroquinolones on the expression of matrix metalloproteinase in debrided cornea of rats. *Toxicol Mech Methods* 2011; 21(1): 6–12.
47. Sharma N, Goel M, Bansal S, Agarwal P, Titiyal JS, Upadhyaya AD, et al. Evaluation of moxifloxacin 0.5% in treatment of nonperforated bacterial corneal ulcers: A randomized controlled trial. *Ophthalmology* 2013; 120(6): 1173–8.
48. Ray KJ, Prajna L, Srinivasan M, Geetha M, Karpagam R, Glidden D, et al. Fluoroquinolone treatment and susceptibility of isolates from bacterial keratitis. *JAMA Ophthalmol* 2013; 131(3): 310–3.
49. Kowalski RP, Kowalski TA, Shanks RM, Romanowski EG, Karenchak LM, Mab FS. In vitro comparison of combination and monotherapy for empiric and optimal coverage of bacterial keratitis based on incidence of infection. *Cornea* 2013; 32(6): 830–4.
50. Chawla B, Agarwal P, Tandon R, Titiyal JS, Sharma N, Agarwal T, et al. In vitro susceptibility of bacterial keratitis isolates to fourth-generation fluoroquinolones. *Eur J Ophthalmol* 2010; 20(2): 300–5.
51. Matsuura K. Pharmacokinetics of subconjunctival injection of moxifloxacin in humans. *Graefes Arch Clin Exp Ophthalmol* 2013; 251(3): 1019–20.
52. Keating GM. Moxifloxacin 0.5% ophthalmic solution: In bacterial conjunctivitis. *Drugs* 2011; 71(1): 89–99.
53. Oum BS, Kim NM, Lee JS, Park YM. Effects of fluoroquinolones eye solutions without preservatives on human corneal epithelial cells in vitro. *Ophthalmic Res* 2014; 51(4): 216–23.
54. Watanabe R, Nakazawa T, Yokokura S, Kubota A, Kubota H, Nishida K. Fluoroquinolones antibacterial eye drops: Effects on normal human corneal epithelium, stroma, and endothelium. *Clin Ophthalmol* 2010; 4(10): 1181–7.
55. Chen TC, Chang SW, Wang TY. Moxifloxacin modifies corneal fibroblast-to-myofibroblast differentiation. *Br J Pharmacol* 2013; 168(6): 1341–54.
56. Agarwal T, Jhanji V, Satpathy G, Nayak N, Chawla B, Tandon R, et al. Moxifloxacin resistance: Intrinsic to antibiotic or related to mutation. *Optom Vis Sci* 2012; 89(12): 1721–4.
57. Datot M, Pouz F. Fluoroquinolone eye drop-induced cytotoxicity: Role of preservative in P2X7 cell receptor activation and apoptosis. *Invest Ophthalmol Vis Sci* 2006; 47(7): 2812–9.
58. Le Feuvre R, Brough D, Rothwell N. Extracellular ATP and P2X7 receptors in neurodegeneration. *Eur J Pharmacol* 2002; 447(2–3): 261–9.
59. Miras-Portugal MT, Diaz-Hernandez M, Giraldez L, Herras C, Gomez-Villafuertes R, Sen RP, et al. P2X7 receptors in rat brain: Presence in synaptic terminals and granule cells. *Neurochem Res* 2003; 28(10): 1597–605.
60. Labasi JM, Petrushova N, Donovan C, McCurdy S, Lira P, Payette MM, et al. Absence of the P2X7 receptor alters leukocyte function and attenuates an inflammatory response. *J Immunol* 2002; 168(12): 6436–45.
61. Dell'Antonio G, Quattrini A, Cin ED, Fulgenzi A, Ferrero ME. Relief of inflammatory pain in rats by local use of the selective P2X7 ATP receptor inhibitor, oxidized ATP. *Arthritis Rheum* 2002; 46(12): 3378–85.
62. Colomar A, Marty V, Medina C, Combe C, Parnet P, Amedee T. Maturation and release of interleukin-1beta by lipopolysaccharide-primed mouse Schwann cells require the stimulation of P2X7 receptors. *J Biol Chem* 2003; 278(33): 30732–40.
63. Smart ML, Gu B, Panchal RG, Wiley J, Cromer B, Williams DA, et al. P2X7 receptor cell surface expression and cytolytic pore formation are regulated by a distal C-terminal region. *J Biol Chem* 2003; 278(10): 8853–60.
64. Gasset AR. Benzalkonium chloride toxicity to the human cornea. *Am J Ophthalmol* 1977; 84(2): 169–71.
65. Sheikh A, Hurvitz B, van Schayck CP, Mclean S, Nurmatov U. Antibiotics versus placebo for acute bacterial conjunctivitis. *Cochrane Database Syst Rev* 2012; 12(9): CD001211.

Received on April 26, 2016.

Revised on June 2, 2016.

Accepted on June 8, 2016.

Online First October, 2016.