



Malignant fibrous histiocytoma of the right upper leg – A case report

Malignni fibrozni histiocitom desne natkolenice

Mladen Pavlović*†, Bojan Milošević*†, Dragče Radovanović*†, Aleksandar Cvetković*†, Trifunović Bratislav*§, Dragan Čanović*†, Slobodanka Mitrović||, Milan Jovanović*§, Marko Spasić*†, Maja Vulović§¶, Bojan Stojanović*†, Dejan Jeremić¶, Jasna Jevdjić†**

Clinical Center Kragujevac, *Clinic for General and Thoracic Surgery, ||Department of Pathology, **Department of Anesthesiology and Reanimatology, Kragujevac, Serbia; University of Kragujevac, †Faculty of Medical Sciences, ¶Department of Anatomy, Kragujevac, Serbia; Military Medical Academy, ‡Clinic for General Surgery, Belgrade, Serbia; University of Defence, §Faculty of Medicine of the Military Medical Academy, Belgrade, Serbia

Abstract

Introduction. Malignant fibrous histiocytoma is a fast spreading pleomorphic sarcoma with a high malignant potential. Its spreading is characterized with local invasion and distant metastases with early onset. Most common localisations of development are extremities, trunk and retroperitoneum. Given the line of rare case and specimen, lack of a clear etiology and mechanisms of this disease, as well as adequate histopathologic findings and intraoperative documentation, we presented current status, discuss putative etiology, histopathology with variant morphology, differential diagnosis and treatment modalities. **Case report.** We presented a 56-years-old female Serbian with tumor in the thigh that clinically resembles incapsulated hematoma. Computed tomography revealed intramuscular tumor with a heterodense structure and compression on surround tissue. *Ex tempore* biopsy specimen showed malignant potential of the tumor. Wide and radical excision of the nodule has been done, and definitive histopathological verification revealed malignant fibrous histiocytoma. **Conclusion.** Malignant fibrous histiocytoma is a most common type of soft tissue sarcomas in adults. Frequent localization is on lower extremities, and every rapidly enlarging nodule in this localization that on computed tomography is like incapsulated hematoma with necrotic zone should alert suspicion on presence of this type of sarcoma.

Key words:

sarcoma; soft tissue neoplasms; diagnosis; histological techniques; surgical procedures, operative.

Apstrakt

Uvod. Malignni fibrozni histiocitom je pleomorfni sarkom visokog malignog potencijala koji se brzo širi. Karakteriše se širenjem lokalnom invazijom i ranom pojavom udaljenih metastaza. Najčešće lokalizacije su ekstremiteti, trup i retroperitoneum. S obzirom na redak preparat, nedovoljno jasnu etiologiju i mehanizme nastanka ove bolesti, kao i adekvatan patohistološki nalaz i intraoperativni prikaz, cilj ovog prikaza je bio da se ukaže na trenutna saznanja o ovoj bolesti, njenoj etiologiji, patohistološkim karakteristikama, diferencijalnoj dijagnozi i lečenju. **Prikaz bolesnika.** Prikazana je bolesnica, stara 56 godina, sa tumorom desne natkolenice koji se klinički prezentovao kao inkapsulirani hematoma. Kompjuterizovanom tomografijom utvrđeno je da se radilo o intramuskularnom tumoru koji se komprimovao u okolne strukture. *Ex tempore* biopsija je ukazala na maligni potencijal tumora. Urađena je široka i radikalna ekscizija promene, a definitivni patohistološki nalaz pokazao je da se radilo o malignom fibroznom histiocitomu. **Zaključak.** Malignni fibrozni histiocitom predstavlja najčešći tip sarkoma mekih tkiva kod odraslih. Često je lokalizovan na donjim ekstremitetima. Svaki brzorastući tumefakt mekih tkiva donjih ekstremiteta, koji na snimku kompjuterizovane tomografije podseća na inkapsulirani hematoma sa zonama nekroze, treba da pobudi sumnju na maligni fibrozni histiocitom.

Ključne reči:

sarkomi; meka tkiva, neoplazme; dijagnoza; histološke tehnike; hirurgija, operativne procedure.

Introduction

Malignant fibrous histiocytoma (MFH) is a most common type of soft tissue sarcomas (STS), that was originally

described by Ozzello et al.¹ in 1963 and O'Brien and Stout² in 1964. World Health Organization (WHO) defined MFH as an undifferentiated high grade pleomorphic sarcoma³. It is the most common soft tissue sarcoma in adults, arising

most frequently during the sixth and seventh decades of life⁴. Localisation regarding on the region of the body is as follows: over 70% of cases are located on extremities (50% on lower, and 25% on upper), followed by retroperitoneum (15%), and head and neck in 3–10%⁵. Rare cases include almost every organ in the body – bones, lungs, intestine, greater omentum, scars after surgical incision or even retained gauze⁶. MFH on extremities presents as a slow growing painless mass, while presentation in retroperitoneum is non-specific: appetite and body weight loss, fever and discomfort. It has a great malignant potential, with extensive local spreading and early onset of distant metastases⁷. Regarding on data above, every primary malignant tumor of extremities or retroperitoneum localisation, in people older than 45 years, should be considered as MFH. Recent studies indicate that most probable cells of origin are primitive mesenchymal cells or fibroblastic cells, that have characteristics both of fibroblasts and histiocytes⁸. Given the line of rare case and specimen, lack of a clear etiology, molecular and genetic mechanisms of this disease, we presented literature review, histopathologic findings with variant morphology, intraoperative documentation and modalities of treatment applied to the patient with MFH.

Case report

A 56-year-old female was admitted to our Clinic with the mass in the front of the right thigh. On physical

examination firm tumor with positive fluctuation phenomenon was found and initially impressed like an encapsulated hematoma. Incision was done and material was sent to an *ex tempore* biopsy, which confirmed malignant nature of the mass. Standard blood tests and chest x-rays were normal. Preoperative computed tomography of the right thigh revealed intramuscular tumor (size 65 × 64 × 11 mm), that suppressed surrounding structures. It was of a heterodense structure, peripherally with intensive post-contrast opacification and internally with greater zone of necrosis. Ipsilateral inguinal region and bones tomography were normal (Figure 1).

In general anesthesia, wide local excision and Redon drainage of the wound was done (Figure 2). As expected, patient recovered ?uneventfully.

Histopathology

Operating material was sent for histopathologic analysis. Grossly, the tumor at the intersection was of whitish color, vitreous luster, with yellowish areas of necrosis and hemorrhage. Tumor samples were fixed in formalin, embedded in paraffin, cut into the cryotome in 4 μ thick tissue sections and stained with standard hematoxylin and eosine (HE) staining method. Microscopically, the tumor showed a classic image of a giant cell type MFH. It was built out from

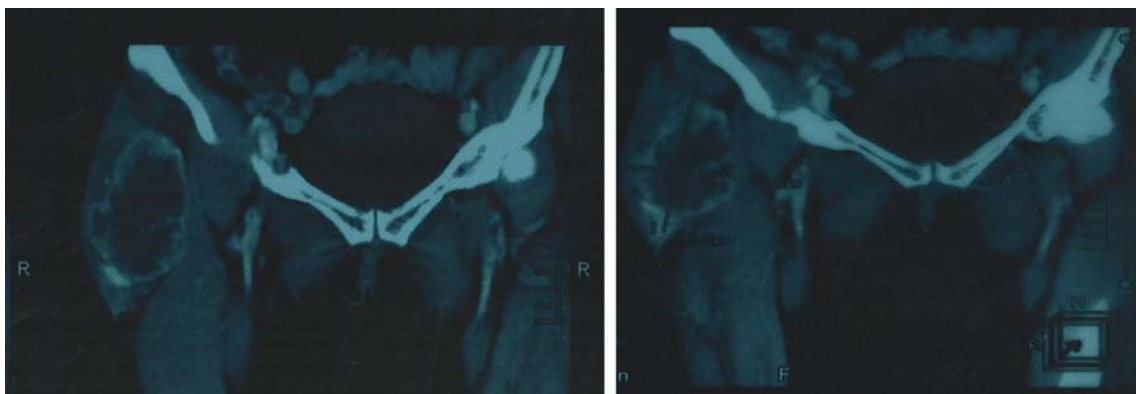

Fig. 1 – Computed tomography (CT) examination of the right femoral region shows an expansive heterodense tumor mass within *musculus tensorfascialatae*, internally in the tumor larger zone of necrosis can be seen.

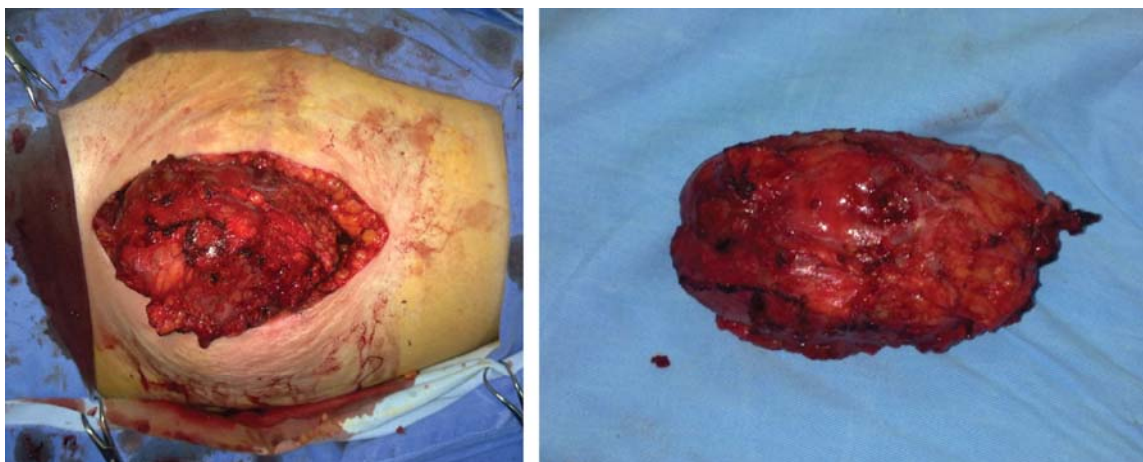

Fig. 2 – Intraoperative findings: large encapsulated tumor of the right thigh with clean resection margins.

the storiform arranged connective cells, along with zones dominated by histiocytes, among which there were numerous multinucleated giant osteoclast type cells (Figure 3).

Discussion

MFH is a group of pleomorphic neoplasm that have similar morphological characteristics. There are many different histopathological images which can be grouped into 4 subtypes, according to the new WHO classification. MFH

ring in only 5–8% of cases. Its characteristic is the existence of intensive inflammatory infiltrate predominantly consisting of neutrophils, lymphocytes and sparkling or anaplastic histiocytes, mainly in the retroperitoneum¹⁰. Angiomatoid MFH was considered as the fifth subtype, but no longer because histologically has similarities with blood vessels, low malignant potential and gives rare metastasis^{11–14}. In the new WHO classification this type is marked as angiomatoid fibrous histiocytoma. MFH is an aggressive sarcoma, with extensive local spreading and early distant metastases. It has

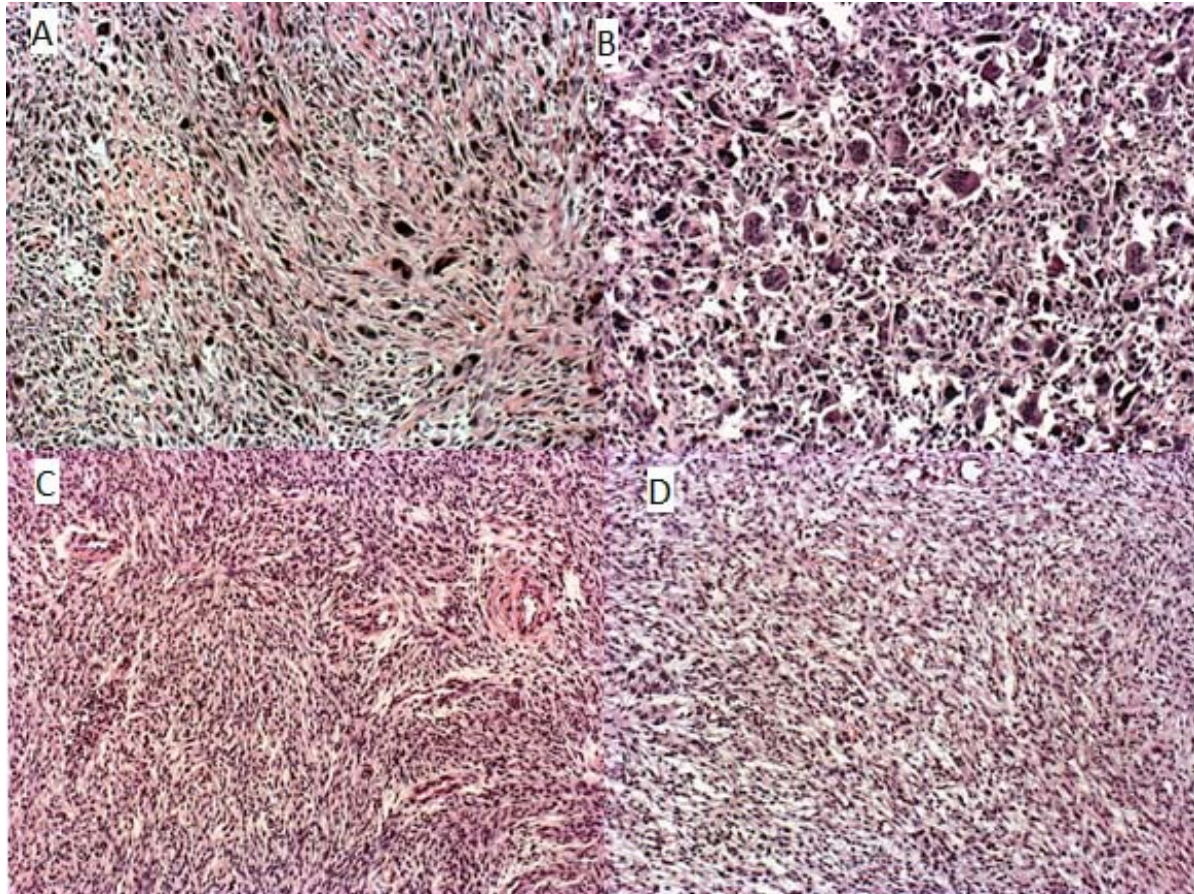


Fig. 3 – The tumor is made up of numerous multinucleate giant cells: A) [hematoxylin eosin (HE), ×200; and B) HE, ×400], which are irregularly scattered in areas storiform arranged connective cells: C) HE, ×100, and D) zones dominated by histiocytes (HE, ×200).

subtypes are: 1) undifferentiated pleomorphic MFH; the largest part, about 65% of MFH, belongs to this group, which are typically composed of a mixture of spindle, polygonal and round cells found in a storiform matrix; it is usually localized to lower extremities and the retroperitoneum mainly in the elderly; 2) myxoid MFH is also common, occurring in 10–20% of cases. It is characterized by myxoid matrix that can be seen under the microscope, otherwise referred to as myxofibrosarcoma and can occur in two forms: superficial and deep⁹; 3) MFH with giant cell variant is less common, occurring in 10–15% of cases of this type. It is characterized by the existence of multinucleate giant cells that can be seen under a microscope; 4) inflammatory MFH is the rarest form, occur-

been determined to exhibit high-grade and biological aggressiveness.

Tumor location, size, and histologic grade directly influence prognosis of MFH. Most commonly metastases occur in the lungs (90%), lymph nodes (12%), bone (8%), and liver (1%)¹⁵. The incidence of regional lymph node involvement is up to 15%^{7,16}.

Risk factors for development of MFH have not been clearly established. Exposure to the ionizing radiation, especially in the MFH of the head and neck, can develop alternative mutations in this tumor. Infarction of the bone is another well-known risk factor^{17,18}. Genetic alterations of the p53 gene is often linked with a poorer prognosis¹⁹, and frequent deletions on

p16^{INK4A} tumor suppressor gene is demonstrated frequently, as well as activation of H- and K- ras gene¹⁹⁻²².

Diagnosis

The diagnosis of MFH is not easy to establish. The presence of the disease may be suspected and the diagnosis can be set on the basis of the following methods: conventional (native) radiography – MFH is seen as a non-specific calcified tissue mass, or can be seen as compression or erosion of the surrounding tissue²³; echosonography (EHO) – seen as well-defined mass that has a complex internal scheme, heteroechoogenic structures with echogenic areas representing the zone cellularity and hypoechoogenic areas representing the zone of necrosis; CT – MFH has mostly muscle density, with hypodense zones representing areas of necrosis; magnetic resonance (MR) – MFH can be visualized as a lobular mass with the intermediate signal on T1 sequences and high signal on T2 sequences²³.

Positron emission tomography/CT scanning is useful on assessing metastases. On angiography scans MFH is seen as a zone of hypervascularisation.

A biopsy has an important place in the diagnosis of MFH. It can be open and needle biopsy. Open biopsy is linked with a higher risk of complications, or less likely diagnoses for non-existence, while in case of the needle biopsy there are opposite results. Sentinel lymph node biopsy is an effective method for evaluating regional disease^{24,25}.

For the histologic diagnosis conventional microscopic picture of MFH on standard HE stained tissue sections is usually sufficient. Alternation of storiform arrangements with connective cells and areas dominated by histiocytes, with variations in presence of giant cells, inflammatory infiltrate, fields of mixoid degeneration or proliferation of blood vessels, depending on the histological subtype of MFH, means that MFH has a potential for bilateral differentiation²⁶. In atypical cases, as an additional method, immunohistochemistry is used, excluding other types of sarcoma by using a broad-spectrum of antibodies of mesenchymal differentiation. Neoplastic cells are positive on vimentin, in about 50% of the epithelial membrane antigen (EMA) and desmin, smooth muscle actin (SMA) and rarely on calponin, but still negative on cytokeratins and protein S-100. The pre-B cell antigen LN-2 (CD74) is a marker which helps distinguish MFH from atypical fibroxanthoma (AFX). The presence of immunohistochemical marker, bone morphogenic protein 2, gives better prognosis for patients²⁷. Focal or weak immunoreactivity to mesenchymal markers such as CD10, CD99, CD68, lysozyme, fascin, and other intermediated filaments like desmin and neurofilaments has already been observed in cases of MFH⁵.

Treatment

The goal of treatment is wide surgical resection of the tumor with clear resection margins²⁸.

The most common form of surgical treatment is the early and complete surgical excision with *en bloc* lymph dissection. In some cases, as a therapeutic option for the solution of MFH, amputation of limb is considered. After tumor resection, as an

integral part of the surgical treatment reconstructive procedures are followed²⁹. Studies in last two decades have demonstrated that conservative surgery, with or without adjuvant therapy, appears to be an effective treatment for sarcomas, including high-grade sarcomas, with a local recurrence rate of 7–15%, with no significant differences in terms of overall survival and disease-free interval compared with amputation³⁰⁻³².

After surgery, chemotherapy is usually applied - doxorubicin, or gemcitabine or a combination of doxorubicin and dacarbazine, and doxorubicin, ifosfamide and mesna. MFH treatment protocols depend on several factors: the size of the primary lesion, metastasis, localization near the vascular or visceral structures, patient's age, general condition. The basic method of treatment is radical surgery: complete removal of tumor and surrounding structures, while in those tumors that are localized near the vascular and nerve elements marginal surgical excision through the fibrous tissue that surrounds sarcoma is performed. Oncology goal of surgery is to achieve clean edges with no tumor cells.

Irradiation is carried out with the aim of reducing the probability of local recurrence and metastasis. It may be preoperative, intraoperative and postoperative. The dose of radiation ranges from 40–65 Gy and depends on the extensiveness of surgical treatment, localization of resection edges and whether they contain or not microscopic or macroscopic tumor cells.

Chemotherapy protocol that is used in the treatment is referred to as mesna, doxorubicin, ifosfamide, and dacarbazine (MAID)³³. So far, chemotherapy is employed only for widespread disease, but large trials have not shown a significant benefit^{34,35}. Multiple tyrosine kinase inhibitor, sunitinib, for MFH is currently undergoing a phase II trial³⁶, and phase I trial investigating ipilimumab in the treatment of MFH is in progress³⁷.

A characteristic of MFH is an increased incidence of local recurrence of the disease. Neoplastic infiltration of the resection margins at the end of surgery appears to be among the major factors affecting the rate of local recurrence. In fact, the local recurrence rate approximates 13% with margins of < 1 cm, while it may be reduced to 0% in cases with margins more than 1 cm. Previous studies have shown that 19–64% of patients with MFH developed local recurrences^{16,38}. The recurrence rate of MFH in extremities was lower than that in other areas. Local recurrence rates in extremities have been reported to be 19–38%^{3,39}. Factors that indicate a poor prognosis are lesions over 5 cm, positive edges and local recurrence, while the most important prediction factor for distant metastasis is the size of the primary lesion, especially over the size of 5 cm⁴⁰.

The general outcomes of extremity MFHs are superior to those of head and neck and retroperitoneal MFHs. According to a study conducted by Chen et al.⁴¹, 5-year survival rate is 76.2%. Clinical outcomes of extremity MFHs are associated with multiple factors. A French multicenter study of 410 patients with soft tissue sarcoma showed that tumor staging, resection margin, tumor location, histology type, and age of the patients are independent predictors of 5-year survival⁴². In regard of the size of the tumor, 5-year

survival for tumors < 5 cm is 82%, then falls to 68% for 5- to 10-cm tumors, and 51% for tumors >10 cm^{24, 33}.

Conclusion

MFH represents a rare and mysterious type of STS that requires timely diagnosis and aggressive treatment approach. For better survival results it is necessary to re-examine and adopt treatment protocols, especially with new biological agents and mole-

cular – targeted therapy. Adjuvant therapy should be individually based. Understanding etiology, pathogenesis and genetic mechanisms that leads to this disease still remains controversial.

Acknowledgement

The part of this research is supported by Ministry of Education, Science and Technological Development of the Republic of Serbia, Grants III41007 and III41010.

R E F E R E N C E S

- Ozzello L, Stout AP, Murray MR. Cultural characteristics of malignant histiocytomas and fibrous xanthomas. *Cancer* 1963; 16(3): 331–44.
- O'Brien JE, Stout AP. Malignant fibrous xanthomas. *Cancer* 1964; 17: 1445–55.
- Vasileios KA, Eward WC, Brigman BE. Surgical treatment and prognosis in patients with high-grade soft tissue malignant fibrous histiocytoma of the extremities. *Arch Orthop Trauma Surg* 2012; 132(7): 955–61.
- Henderson MT, Hollmig ST. Malignant fibrous histiocytoma: Changing perceptions and management challenges. *J Am Acad Dermatol* 2012; 67(6): 1335–41.
- Karkos PD, Dova S, Sotiriou S, Markou K, Kostopoulos I. Double primary malignant fibrous histiocytoma and squamous cell carcinoma of the larynx treated with laser laryngeal conservation surgery. *Ecancelmedicalscience* 2016; 10: 636.
- Kaplan M, Iyiköşker H. A new complication of retained surgical gauze: development of malignant fibrous histiocytoma: Report of a case with a literature review. *World J Surg Oncol* 2012; 10: 139.
- Weiss SW, Enzinger FM. Malignant fibrous histiocytoma: An analysis of 200 cases. *Cancer* 1978; 41(6): 2250–66.
- Luşar B, Calonje E. Cutaneous fibrohistiocytic tumours: An update. *Histopathology* 2010; 56(1): 148–65.
- Mentzel T, Calonje E, Wadden C, Camplejohn RS, Beham A, Smith MA, et al. Myxofibrosarcoma. Clinicopathologic analysis of 75 cases with emphasis on the low-grade variant. *Am J Surg Pathol* 1996; 20(4): 391–405.
- Ghosh A, Dwivedi US, Kumar A. Inflammatory malignant fibrous histiocytoma of kidney: A case report. *Pathol Res Pract* 2008; 204(11): 857–61.
- Guo H, Xiong Y, Nong L, Zhang S, Li T. Reassessment of the pathological diagnosis in 33 cases of malignant fibrous histiocytoma. *Beijing Da Xue Xue Bao* 2008; 40(4): 374–9. (Chinese)
- Thway K, Fisher C. Angiomatoid fibrous histiocytoma: The current status of pathology and genetics. *Arch Pathol Lab Med* 2015; 139(5): 674–82.
- Tataroglu C, Çulbaci N, Çeçen E. Angiomatoid fibrous histiocytoma: Case report and review of the literature. *Turk J Pediatr* 2015; 57(1): 102–4.
- Rekhi B, Adamane S, Ghodke K, Desai S, Jambhekar NA. Angiomatoid fibrous histiocytoma: Clinicopathological spectrum of five cases, including EWSR1-CREB1 positive result in a single case. *Indian J Pathol Microbiol* 2016; 59(2): 148–52.
- Eguíluz Lumbreras P, Palacios Hernández A, Heredero Zorzo O, García García J, Cañada de Arriba F, Pérez Herrero F, et al. Retroperitoneal malignant fibrous histiocytoma: case report. *Arch Esp Urol* 2010; 63(6): 477–9.
- Kearney MM, Soule EH, Ivins JC. Malignant fibrous histiocytoma: A retrospective study of 167 cases. *Cancer* 1980; 45(1): 167–78.
- Michael RH, Dorfman HD. Malignant fibrous histiocytoma associated with bone infarcts: Report of a case. *Clin Orthop Relat Res* 1976; 118: 180–3.
- Clark DW, Moore BA, Patel SR, Guadagnolo BA, Roberts DB, Sturgis EM. Malignant fibrous histiocytoma of the head and neck region. *Head Neck* 2011; 33(3): 303–8.
- Reid AH, Tsai MM, Venzon DJ, Wright CF, Lack EE, O'leary TJ. MDM2 amplification, P53 mutation, and accumulation of the P53 gene product in malignant fibrous histiocytoma. *Diagn Mol Pathol* 1996; 5(1): 65–73.
- Franchi A, Santucci M. Tenascin expression in cutaneous fibrohistiocytic tumors. Immunohistochemical investigation of 24 cases. *Am J Dermatopathol* 1996; 18(5): 454–9.
- Simons A, Schepens M, Jenken J, Sprenger S, van de Zande G, Bjerke-bagen B, et al. Frequent loss of 9p21 (p16(INK4A)) and other genomic imbalances in human malignant fibrous histiocytoma. *Cancer Genet Cytogenet* 2000; 118(2): 89–98.
- Sakamoto A, Oda Y, Itakura E, Oshiro Y, Tamija S, Honda Y, et al. H-, K-, and N-ras gene mutation in atypical fibroxanthoma and malignant fibrous histiocytoma. *Hum Pathol* 2001; 32(11): 1225–31.
- Murphey MD, Gross TM, Rosenthal HG. From the archives of the AFIP. Musculoskeletal malignant fibrous histiocytoma: Radiologic-pathologic correlation. *Radiographics* 1994; 14(4): 807–8; quiz 827–8.
- Al-Agha OM, Igbokwe AA. Malignant fibrous histiocytoma: Between the past and the present. *Arch Pathol Lab Med* 2008; 132(6): 1030–5.
- Weingrad DN, Rosenberg SA. Early lymphatic spread of osteogenic and soft-tissue sarcomas. *Surgery* 1978; 84(2): 231–40.
- Hartel PH, Brattbauer G, Hartel JV, Fanburg-Smith JC. Primary malignant fibrous histiocytoma (myxofibrosarcoma/pleomorphic sarcoma not otherwise specified) of the breast: Clinicopathologic study of 19 cases. *Ann Diagn Pathol* 2011; 15(6): 407–13.
- Asano N, Yamakazi T, Seto M, Matsumine A, Yoshikawa H, Uchida A. The expression and prognostic significance of bone morphogenetic protein-2 in patients with malignant fibrous histiocytoma. *J Bone Joint Surg* 2004; 86(4): 607–12.
- Zagars GK, Ballo MT, Pisters PW, Pollock RE, Patel SR, Benjamin RS, et al. Prognostic factors for patients with localized soft-tissue sarcoma treated with conservation surgery and radiation therapy: An analysis of 1225 patients. *Cancer* 2003; 97(10): 2530–43.
- Mankin HJ, Hornicek FJ. Diagnosis, classification, and management of soft tissue sarcomas. *Cancer Control* 2005; 12(1): 5–21.
- Rosenberg SA, Tepper J, Glatstein E, Costa J, Baker A, Brennan M, et al. The treatment of soft-tissue sarcomas of the extremities: Prospective randomized evaluations of (1) limb-sparing surgery plus radiation therapy compared with amputation and (2) the role of adjuvant chemotherapy. *Ann Surg* 1982; 196(3): 305–15.
- Baldini EH, Goldberg J, Jenner C, Manola JB, Demetri GD, Fletcher CD, et al. Long-term outcomes after function-sparing surgery without radiotherapy for soft tissue sarcoma of the extremities and trunk. *J Clin Oncol* 1999; 17(10): 3252–9.

32. *Lin PP, Guzel VB, Pisters PWT, Zagars GK, Weber KL, Feig BW*, et al. Surgical management of soft tissue sarcomas of the hand and foot. *Cancer* 2002; 95(4): 852–61.
33. *Al-Absi E, Farrokhlyar F, Sharma R, Whelan K, Corbett T, Patel M*, et al. A systematic review and meta-analysis of oncologic outcomes of pre- versus postoperative radiation in localized resectable soft-tissue sarcoma. *Ann Surg Oncol* 2010; 17(5): 1367–74.
34. *Marchese R, Bufo P, Carrieri G, Bove G*. Malignant fibrous histiocytoma of the kidney treated with nephrectomy and adjuvant radiotherapy: A case report. *Case Rep Med* 2010; 2010. pii: 802026.
35. *Todoroki T, Kondo T, Sugahara S, Morishita Y, Mori K, Ohno T*. Long-term survivor of relapsed MFH on the thigh treated with autologous formalin-fixed tumor vaccine (AFTV) combined with limb-sparing surgery and radiotherapy. *World J Surg Oncol* 2011; 9: 96.
36. *Mahmood ST, Agresta S, Vigil CE, Zhao X, Han G, D'amato G*, et al. Phase II study of sunitinib malate, a multitargeted tyrosine kinase inhibitor in patients with relapsed or refractory soft tissue sarcomas. Focus on three prevalent histologies: Leiomyosarcoma, liposarcoma and malignant fibrous histiocytoma. *Int J cancer* 2011; 129(8): 1963–9.
37. *Uehara T, Fujiwara T, Takeda K, Kunisada T, Ozaki T, Udono H*. Immunotherapy for Bone and Soft Tissue Sarcomas. *Biomed Res Int* 2015; 2015: 820813.
38. *Sabesan T, Xuexi W, Yongfa Q, Pingzhang T, Ilankovan V*. Malignant fibrous histiocytoma: Outcome of tumours in the head and neck compared with those in the trunk and extremities. *Br J Oral Maxillofac Surg* 2006; 44(3): 209–12.
39. *Bertoni F, Capanna R, Biagini R, Bacchini P, Guerra A, Ruggieri P*, et al. Malignant fibrous histiocytoma of soft tissue. An analysis of 78 cases located and deeply seated in the extremities. *Cancer* 1985; 56(2): 356–67.
40. *Nascimento AF, Raut CP*. Diagnosis and management of pleomorphic sarcomas (so-called "MFH") in adults. *J Surg Oncol* 2008; 97(4): 330–9.
41. *Chen KH, Chou TM, Shieh SJ*. Management of extremity malignant fibrous histiocytoma: A 10-year experience. *Formos J Surg [Internet]* 2016; 48(1): 1–9.
42. *Guillou L, Coindre JM, Bonichon F, Nguyen BB, Terrier P, Collin F*, et al. Comparative study of the National Cancer Institute and French Federation of Cancer Centers Sarcoma Group grading systems in a population of 410 adult patients with soft tissue sarcoma. *J Clin Oncol* 1997; 15(1): 350–62.

Received on May 12, 2016.

Revised on September 08, 2016.

Accepted on September 12, 2016.

Online First September, 2016.