



## The expression and significance of p53 protein and Ki-67 protein in pterygium

### Ekspresija i značaj proteina p53 i Ki-67 u pterigijumu

Vesna Ljubojević<sup>\*†</sup>, Radoslav Gajanin<sup>\*\*‡</sup>, Ljiljana Amidžić<sup>\*†</sup>,  
Zoran Vujković<sup>\*\*§</sup>

<sup>\*</sup>Faculty of Medicine, University of Banja Luka, Banja Luka, Bosnia and Herzegovina;

<sup>†</sup>Department of Histology and Embriology, <sup>‡</sup>Department of Pathology, <sup>§</sup>Clinic of  
Neurology, Clinical Center Banja Luka, Banja Luka, Bosnia and Herzegovina

#### Abstract

**Background/Aim.** Pterygium is considered to be a degenerative disease of the conjunctiva, however, the presence of tumor markers in pterygium reinforces the hypothesis that this lesion is similar to tumor. Inactivation of p53 function removes an obstacle to increased proliferation. Factors affecting the prevalence of p53 expression in pterygium deserve investigation. The aim of the study was to investigate the expression of p53 and Ki-67 proteins in pterygium and normal conjunctiva, the effects of gender and age on p53 expression, and the relationship between the expression of p53 and Ki-67 proteins. **Methods.** A total of 34 samples of pterygium and 34 samples of the normal conjunctiva were analyzed. The samples were studied by immunohistochemistry using antibodies against p53 and Ki-67. **Results.** Totally 15 (44%) samples of pterygia were p53 positive. Correlations between the expression of p53 protein and sex, and age were not established. The number of Ki-67 positive cells in pterygium (9.74%) was significantly higher than the number of Ki-67 positive cells in the normal conjunctiva (1.74%), ( $p = 0.001$ ). Between the expression of p53 protein and Ki-67 protein in pterygium there was a significant positive correlation ( $p = 0.000$ ). **Conclusion.** The prevalence of p53 positive samples of pterygium was 44%. The influence of sex and age on p53 protein expression in pterygium was not found. The increased proliferative activity was present in the epithelium of pterygium. The expression of Ki-67 protein is associated with the expression of p53 protein in pterygium. The findings of our study support the thesis of pterygium as tissue growth disorder.

#### Key words:

pterygium; tumor markers, biological; tumor suppressor protein p53; conjunctiva; age factors; sex; immunohistochemistry.

#### Apstrakt

**Uvod/Cilj.** Pterigijum se smatra degenerativnim oboljenjem konjunktive, međutim, nalaz tumorskih markera u pterigijumu pojačava hipotezu da je to lezija slična tumoru. Inaktivacija p53 funkcije uklanja prepreku povećanju proliferacije. Faktori koji utiču na prevalenciju p53 ekspresije u pterigijumu zaslužuju ispitivanje. Cilj rada bio je da se istraži ekspresija p53 i Ki-67 proteina u pterigijumu i normalnoj konjunktivi, uticaj životnog doba i pola na ekspresiju p53 proteina, kao i odnos između ekspresije p53 i Ki-67 proteina. **Metode.** Analizirani su 34 uzorka pterigijuma i 34 uzorka normalne konjunktive. Uzorci su analizirani imunohistohemijskim metodama uz korišćenje antitela za p53 i Ki-67. **Rezultati.** Ukupno 15 (44%) uzoraka bilo je p53 pozitivno. Povezanost između ekspresije p53 proteina i pola, kao i starosti nije utvrđena. Broj Ki-67 pozitivnih ćelija u pterigijumu (9,74%) bio je značajno veći od broja Ki-67 pozitivnih ćelija u normalnoj konjunktivi (1,74%), ( $p = 0,001$ ). Između ekspresije proteina p53 i proteina Ki-67 u epitelu pterigijuma nađena je značajna pozitivna korelacija ( $p = 0,000$ ). **Zaključak.** Prevalencija p53 pozitivnih uzoraka pterigijuma bila je 44%. Nije utvrđen uticaj pola i životnog doba na ekspresiju proteina p53 u pterigijumu. U epitelu pterigijuma prisutna je povećana proliferativna aktivnost. Ekspresije proteina p53 i proteina Ki-67 u epitelu pterigijuma pozitivno su povezane. Nalazi naše studije podržavaju tezu o pterigijumu kao poremećaju rasta tkiva.

#### Ključne reči:

pterygium; tumorski markeri, biološki; protein p53; konjunktiva; životno doba, faktori; pol; imunohistohemija.

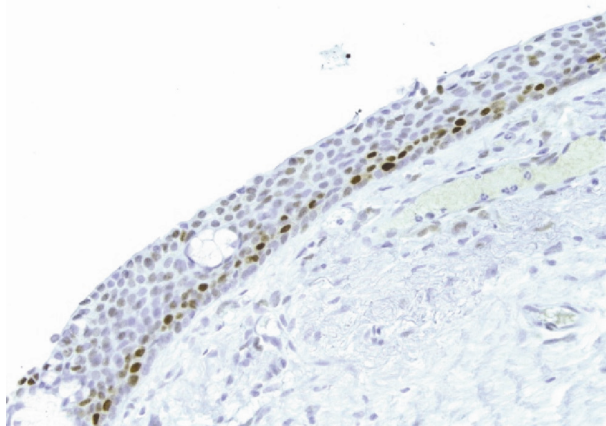
## Introduction

Pterygium is a fibrovascular conjunctival lesion and its etiology and pathogenesis are unclear<sup>1-3</sup>. For a long time, it was considered as a degenerative disease. Chronic inflammatory infiltrate, consisting of T lymphocytes, macrophages, plasma cells and mast cells, is present in pterygium<sup>4, 5</sup>. However, finding of tumor markers, such as p53, reinforces the hypothesis that the pterygium represents a lesion similar to tumor<sup>6-9</sup>. Protein p53 is the guardian of the physical integrity of the cellular genome and inactivation of p53 function eliminates a major barrier for tumorigenesis and increased proliferation. The prevalence of p53 positive samples of pterygium is within a wide range of 7.9% to 100%<sup>10-16</sup>. The cause of the different prevalence of p53 protein expression remains unknown. Race, different parts of pterygium, p53 gene mutation spectrum, gender and age may affect the result of immunohistochemical analysis and should be further investigated<sup>10</sup>. Proliferative cellular activity can be evaluated by the detection of Ki-67 nuclear protein that is essential for the maintenance of the cell cycle. The expressions of p53 and Ki-67 proteins are useful markers of early premalignant lesions<sup>17-19</sup>.

The aim of this study was to investigate the expression of p53 protein and Ki-67 protein in pterygium and normal conjunctiva, the influence of age and sex on the expression of p53 protein, and the relationship between the expression of p53 protein and Ki-67 protein in pterygium.

## Methods

The study was done on 34 surgically excised pterygia (21 women, 13 men, age from 39 to 82 years) at the Clinical Center, Banjaluka, and 34 samples of normal bulbar conjunctiva (16 woman, 18 men, age from 44 to 82 years) taken during cataract surgery. Excised tissue of pterygium was fixed in 10% buffered formalin and processed for paraffin-embedded sections. The samples were oriented so that the cut was made perpendicular to the epithelium, and longitudinally through the body and the head of pterygium. The 4 µm thick histological sections were deparaffinized and rehydrated.



**Fig. 1 – p53 positive cells in pterygium (anti-p53, ×200).**

To detect primary antigens p53 and Ki-67 after standard procedures, histological sections were subjected to immunoperoxidase staining techniques. We used commercial monoclonal mouse anti-human p53 antibody clone DO-7 (Dako®, Code M7001) at 1 : 25 dilutions and monoclonal mouse anti-human Ki-67 antibody clone MIB-1 (Dako®, Code M7240) at 1:100 dilutions. For visualization we used the EnVision system (Dako® Code K4000) and chromogene DAB Liquid (Dako® Code K3467).

The expressions of p53 and Ki-67 proteins in the epithelium and stroma were estimated quantitatively. We counted at least 100 cells of tissue (including immunopositive cells) in three microscopic fields (magnification ×200) from pterygium tissue. The expression of p53 protein was marked as “p53 positive” if the p53 protein was present in more than 10% of tissue cells, and as “p53 negative” if the p53 protein was present in less than 10% of cells (cut-off level was set at 10%).

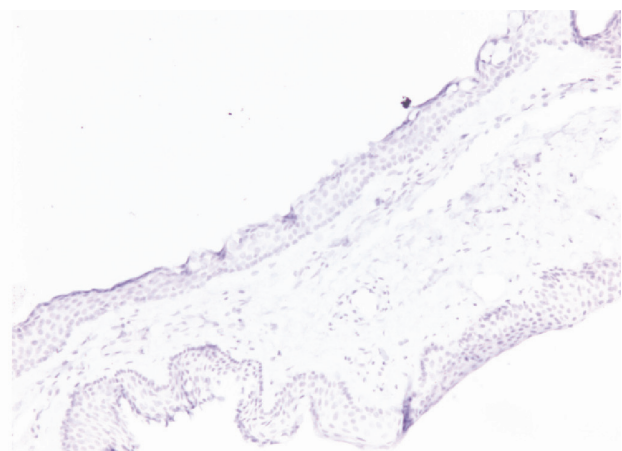
The number of Ki-67 positive cells was expressed as a percentage.

Examination of histological sections was performed using a Leica DM 6000 B microscope equipped with a digital camera Leica Microsystems Camera DFC495. For acquisition and display of digital images the Leica Application Suite software has been used.

The results were analyzed by methods of descriptive and correlative statistics. Statistical analysis was performed using the SPSS software (version 15.0), and the following tests were applied: chi square test, Student’s *t*-test, Pearson’s test, Spearman’s *rho* test.

## Results

It was found that the epithelium of pterygium was positive in 15 (44%) samples. Four the samples of pterygium with 4%, 5%, 6% and 9% of p53 positive cells, were taken as p53 negative. Nuclei of epithelial cells positive for p53 protein were mainly located in the basal and parabasal layers of the epithelium (Figure 1). According to the p53 expression in the stroma of pterygium, samples were negative. In the control group, there were no samples positive for p53 protein (Figure 2).

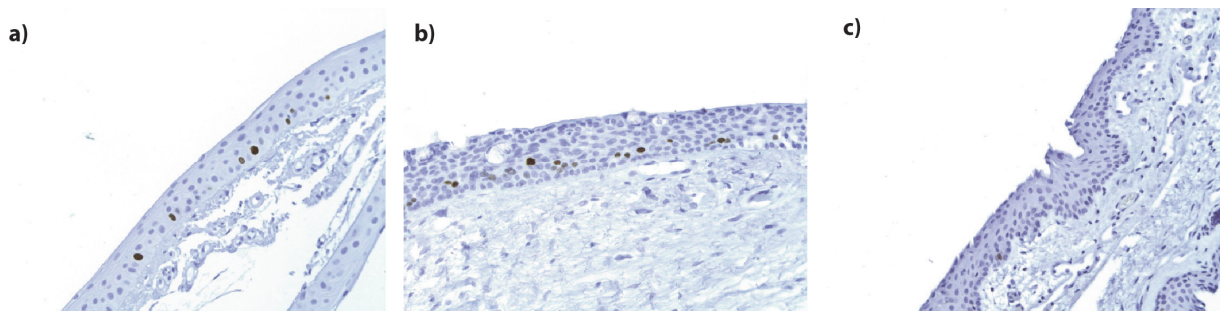


**Fig. 2 – The sample of normal conjunctiva is negative for p53 expression (anti-p53, ×100).**

Among p53 positive samples of pterygium there were seven men and eight women. No statistically significant difference in frequencies between the groups was found ( $\chi^2 = 0.808$ ,  $df = 1$ ,  $p = 0.369$ ). The difference in the expression of p53 protein between men and women was not found.

There was no significant correlation between the positive expression of p53 protein in samples of pterygium and age ( $r = -0.113$ ,  $p = 0.337$ ).

Nuclei positively stained for nuclear proliferation protein Ki-67 were found in the epithelium of pterygium and normal conjunctiva (Figure 3). Nuclei positive for Ki-67 were located mainly in the basal and parabasal layers of the epithelium (Figure 3).



**Fig. 3 – Ki-67 positive cells in the epithelium of: a) pterygium head, b) pterygium body; and c) normal conjunctiva (anti-Ki-67,  $\times 200$ ).**

All parts of pterygium epithelium were not positive for Ki-67, and the distribution of positive cells was uneven. To determine the number of Ki-67 positive cells in the head and body of the pterygium, parts of the epithelium with the highest density were taken. No positively stained nuclei for Ki-67 were found in goblet cells and stroma of pterygium and normal conjunctiva. The average value of Ki-67 positive cells in the epithelium of pterygium head was  $9.74\% \pm 13.14$  (mean  $\pm$  standard deviation). In the epithelium of pterygium body  $4.65\% \pm 5.99$  of Ki-67 positive cells was found (Table 1). The number of Ki-67 positive cells in the head of pterygium was significantly higher as compared to the body of pterygium ( $t = 2.05$ ,  $p = 0.044$ ).

**Table 1**  
**Ki-67 protein expression in pterygium and normal conjunctiva tissue**

Tissue samples	Ki-67 positive cells (%)
	$\bar{x} \pm SD$
Normal conjunctiva	$1.74 \pm 1.56$
Pterygium head	$9.74 \pm 13.14$
Pterygium body	$4.65 \pm 5.99$

In normal conjunctiva the average number of Ki-67 positive cells was  $1.74\% \pm 1.56$  (Table 1). The average number of Ki-67 positive cells in the epithelium of pterygium of  $9.74\%$  was significantly higher than the average value of Ki-67 positive cells in normal conjunctival epithelium of  $1.74\%$  ( $t = 3.451$ ,  $p = 0.001$ ).

In the epithelium of pterygium, an association between the expression of p53 protein and Ki-67 protein was found. The parts of the epithelium which showed immunopositivity for p53 were, at the same time, immunopositive for Ki-67 (Figures 1 and 3b, respectively).

There was a statistically significant positive correlation between the expression of p53 protein and Ki-67 protein in the epithelium of pterygium ( $r = 0.828$ ,  $p = 0.000$ ).

## Discussion

A total of 44% of pterygium samples were p53 positive. In studies the presence of elevated level of stabilized p53

protein which can be detected by immunohistochemistry in the epithelium of pterygium has been found<sup>2, 10-16</sup>. Previous studies found that the prevalence of p53 positive pterygium were inside of a wide range of 7.9% to 100%<sup>10-16</sup>. Using the antibody DO1 Dushku et al.<sup>6</sup> found, immunopositivity for p53 protein in 100% of analyzed pterygia. Onur et al.<sup>12</sup> determined the expression of p53 protein in 7.9% of the analyzed samples of pterygium. Using antibody DO7 and the cut off level set at 10%, Tan et al.<sup>2</sup> found 60%, Weinstein et al.<sup>13</sup> 54%, and Tsai et al.<sup>10, 15</sup> 21.6% p53 positive samples of pterygium. Khalfaoui et al.<sup>16</sup> found positive p53 expression in 100% of analyzed pterygium, of which 75% of samples had the expression higher than 25% positive epithelial cells. Among the factors considered to affect the prevalence of p53 positive cases of pterygium were gender and age.

The difference in the expression of p53 protein between men and women was not found ( $p = 0.369$ ). The same results have already been published by Khalfaoui et al.<sup>16</sup>, Tsai et al.<sup>10</sup>, and Perra et al.<sup>14</sup>. The absence of significant correlation between sex and p53 expression is explained by the fact that examined patients, whether men or women, were exposed to the same environmental conditions. Conversely, Ueda et al.<sup>11</sup> found a significantly higher prevalence of p53 expression in males.

Between the positive expression of p53 protein in samples of pterygium and age there was no significant correlation ( $p = 0.337$ ). The same results have been published by Ueda et al.<sup>11</sup>, Tan et al.<sup>2</sup>, Tsai et al.<sup>10</sup> and Khalfaoui et al.<sup>16</sup>. This finding does not favor the UV radiation in the etiology of pterygium. Conversely, Perra et al.<sup>14</sup> found the associati-

on between p53 expression and aging. These data are explained by a well-known fact that aging reduces the capacity to repair DNA damage.

The loss of p53 protein function leads to the increased proliferative activity. Nuclear immunopositivity for Ki-67 protein was found in the basal and parabasal layers of the epithelium of pterygium and normal conjunctiva, while it was not found in stroma and goblet cells of the pterygium and normal conjunctiva. A proper orientation of samples and longitudinal sections allow differing parts of pterygium. In the epithelium of pterygium head, the number of Ki-67 positive epithelial cells of 9.74% was significantly higher than the number of Ki-67 positive cells in the epithelium of pterygium body of 4.65% ( $p = 0.044$ ). The number of Ki-67 positive cells in the epithelium of pterygium of 9.74% was significantly higher than the number of Ki-67 positive cells in normal conjunctival epithelium of 1.74% ( $p = 0.001$ ). The same results have been published by Kase et al.<sup>7,8</sup> and Garfias et al.<sup>9</sup>. They found a relatively high proliferative activity of the epithelial cells of pterygium. In the study of Kase et al.<sup>7</sup>, nuclear immunoreactivity for Ki-67 in the head of pterygium was 11.0% of epithelial cells and in the body of pterygium 7.5% epithelial cells, which was significantly higher than immunopositivity in the normal conjunctiva of 2.9%.

Immunohistochemical analysis in our study showed a significant correlation between the expression of p53 protein and Ki-67 protein, indicating increased cell proliferation due to dysfunction of the p53 protein. In pterygium, Shimmura et al.<sup>17</sup> examined the relationship between proliferative cellular activity and p53 protein as guardian of the physical integrity of the cell's genome. They found telomerase activity as a marker of cell proliferation in 58% of analyzed pterygia, but

pterygium samples with increased telomerase activity did not have the simultaneous presence of mutation of the p53 gene, which leads to dysfunction, stabilization and increased level of p53 protein. Tsai et al.<sup>15</sup> have immunohistochemically detected the p53 protein in the absence of its mutation and assumed that human papillomavirus participate in the process of stabilization of p53 protein in the pterygium. In actinic keratosis of the skin, it was found that Ki-67 expression was significantly associated with the proapoptotic marker p53<sup>18</sup>.

### Conclusion

The prevalence of p53 protein positive samples was 44% in pterygium. The influence of sex and age on the expression of p53 protein in pterygium was not found. In the epithelium of pterygium an increased proliferative activity was present. In the epithelium of the pterygium head a higher proliferative activity was present when compared to the body of pterygium. The expression of Ki-67 protein positively correlated with the expression of p53 protein in pterygium. The findings of our study indicate the disorder of apoptosis regulation and cellular proliferation in the epithelium of pterygium, and support the thesis of pterygium as tissue growth disorder.

### Acknowledgements

This investigation was carried out as part of scientific research project entitled "Morphological and immunohistochemical characteristics of pterygial conjunctiva", covered by the Ministry of Science and Technology of the Republic of Srpska, Bosnia and Herzegovina.

### R E F E R E N C E S

1. *Coroneo MT, di Girolamo N, Wakefield D.* The pathogenesis of pterygia. *Curr Opin Ophthalmol* 1999; 10(4): 282–8.
2. *Tan DT, Tang WY, Liu YP, Gob HS, Smith DR.* Apoptosis and apoptosis related gene expression in normal conjunctiva and pterygium. *Br J Ophthalmol* 2000; 84(2): 212–6.
3. *Rodrigues FW, Arruda JT, Silva RE, Moura KK.* TP53 gene expression, codon 72 polymorphism and human papillomavirus DNA associated with pterygium. *Genet Mol Res* 2008; 7(4): 1251–8.
4. *Džunić B, Jovanović P, Zlatanović G, Veselinović D, Petrović A, Stefanović I.* Comparative analysis of histopathological and clinical characteristics of pterygium. *Vojnosanit Pregl* 2010; 67(2): 159–7.
5. *Golu T, Mogoantă L, Streba CT, Pîrîci DN, Mălăeşcu D, Mateescu GO, et al.* Pterygium: histological and immunohistochemical aspects. *Rom J Morphol Embryol* 2011; 52(1): 153–8.
6. *Dushku N, Reid TW.* Immunohistochemical evidence that human pterygia originate from an invasion of vimentin expressing altered limbal epithelial basal cells. *Curr Eye Res* 1994; 13(7): 473–81.
7. *Kase S, Takahashi S, Sato I, Nakanishi K, Yoshida K, Ohno S.* Expression of p27(KIP1) and cyclin D1, and cell proliferation in human pterygium. *Br J Ophthalmol* 2007; 91(7): 958–61.
8. *Kase S, Kitaichi N, Furudate N, Yoshida K, Ohno S.* Increased expression of mucinous glycoprotein KL-6 in human pterygium. *Br J Ophthalmol* 2006; 90(9): 1208–9.
9. *Garfias Y, Bautista-de Lucio VM, Garcia C, Nava A, Villalvaço L, Jimenez-Martinez MC.* Study of the expression of CD30 in pterygium compared to healthy conjunctivas. *Mol Vis* 2009; 15: 2068–73.
10. *Tsai Y, Chang K, Lin C, Lee H, Tsai F, Cheng Y, et al.* p53 Expression in pterygium by immunohistochemical analysis: a series report of 127 cases and review of the literature. *Cornea* 2005; 24(5): 583–6.
11. *Ueda Y, Kanazawa S, Kitaoka T, Dake Y, Ohira A, Ouertani AM, et al.* Immunohistochemical study of p53, p21 and PCNA in pterygium. *Acta Histochem* 2001; 103(2): 159–65.
12. *Onur C, Orhan D, Orhan M, Dizbay Sak S, Tulunay O, Irkeç M.* Expression of p53 protein in pterygium. *Eur J Ophthalmol* 1998; 8(3): 157–61.
13. *Weinstein O, Rosenthal G, Zirkin H, Monos T, Ljshitz T, Argov S.* Overexpression of p53 tumor suppressor gene in pterygia. *Eye* 2002; 16(5): 619–21.
14. *Perra MT, Maxia C, Corbu A, Minerba L, Demurtas P, Colombari R, et al.* Oxidative stress in pterygium: relationship between p53 and 8-hydroxydeoxyguanosine. *Mol Vis* 2006; 12: 1136–42.
15. *Tsai YY, Chang CC, Chiang CC, Yeh KT, Chen PL, Chang CH, et al.* HPV infection and p53 inactivation in pterygium. *Mol Vis* 2009; 15: 1092–7.
16. *Khalfaoui T, Mkannez G, Colin D, Imen A, Zbiba W, Errais K, et al.* Immunohistochemical analysis of vascular endothelial

- growth factor (VEGF) and p53 expression in pterygium from Tunisian patients. *Pathol Biol (Paris)* 2011; 59(3): 137–41.
17. *Shimmura SH, Ishioka M, Hanada K, Shimazaki J, Tsubota K.* Telomerase activity and p53 expression in pterygium. *Invest Ophthalmol Vis Sci* 2000; 41(6): 1364–9.
  18. *da Silva TA, Coelho G, Lorenzetti BA, Figueiredo Cavalcante Neto F.* Expression of apoptotic, cell proliferation regulatory, and structural proteins in actinic keratosis and their association with dermal elastosis. *J Cutan Pathol* 2007; 34(4): 315–23.
  19. *Mullerat J, Deroide F, Winslet MC, Perrett CW.* Proliferation and p53 expression in anal cancer precursor lesions. *Anticancer Res* 2003; 23(3): 2995–9.

Received on April 28, 2014.

Revised on October 26, 2014.

Accepted on November 10, 2014.

Online First November, 2015.