



Effect of diode laser cyclophotocoagulation in treatment of patients with refractory glaucoma

Efekat ciklofotokoagulacije diodnim laserom na lečenje bolesnika sa refraktornim glaukomom

Vladimir Čanadanović^{*†}, Ljiljana Tušek-Lješević^{*}, Aleksandar Miljković^{*†},
Sava Barišić^{*}, Tatjana Bedov^{*†}, Nikola Babić^{*†}

^{*}Eye Clinic, Clinical Center of Vojvodina, Novi Sad, Serbia; [†]Faculty of Medicine, University of Novi Sad, Novi Sad, Serbia

Abstract

Background/Aim. Refractory glaucoma is glaucoma resistant to conventional management (maximally tolerated medical therapy, one or more glaucoma surgeries) and glaucoma in cases of neovascularisation after panretinal photocoagulation or cryoablation. The aim of the study was to determine the intraocular pressure (IOP) lowering efficacy of transscleral diode laser cyclophotocoagulation (DCPC) treatment in the management of pain and IOP in patients with refractory glaucoma. **Methods.** This nonrandomized, retrospective study, included 95 patients (95 eyes) with refractory glaucoma treated at the University Eye Clinic, Clinical Center of Vojvodina, Novi Sad, Serbia, between November 2007 and November 2012 in accordance with the established protocols (16–18 spots, 270°, up to 5J of energy). All the eyes were treated with transscleral DCPC (Iris Medical OcuLight SLx, Iridex Co, Mountain View, USA). Patient's symptoms, bests corrected visual acuity and IOP were recorded 7 days, and 1, 3 and 6 months after the DCPC treatment. **Results.** Out of 95 patients (95 eyes) enrolled in this study 24 (25.2%) were with primary (the group I), and 71 (74.5%) with secondary (the group II) glaucoma. The mean baseline IOP in these two groups was similar: 36.08 ± 8.39 mmHg for the first group and 37.36 ± 8.19 mmHg in the second group. Measurement of the mean IOP in the group I showed the following results: on the day 7 it

was 13.96 ± 8.30 mmHg (62.1% decrease of the baseline value), on the day 30 it was 18.44 ± 8.85 mmHg (48.9% decrease regarding the baseline value), after 3 months it was 22.44 ± 7.36 mmHg (37.8% decrease regarding the baseline value), and after 6 months it was 25.92 ± 7.65 mmHg (28.2% decrease regarding the baseline value). Measurement of IOP in the group II showed the following results: on the day 7 it was 15.77 ± 9.73 mmHg (57.8% decrease of the baseline value), on the day 30 it was 20.14 ± 10.20 mmHg (46.1% decrease regarding the baseline value), after 3 months it was 23.46 ± 9.83 mmHg (37.2% decrease regarding the baseline value) and after 6 months it was 27.23 ± 9.87 mmHg (27.2% decrease regarding the baseline value). Pain was the main symptom in 70 (73.6%) patients before the treatment and it persisted in only 4 (4.2%) of our patients. Other complaints (burning, stinging, foreign body sensation) were experienced by 39 (41%) of the patients, postoperatively. A total of 52 (54.7%) patients had no complaints after the treatment. **Conclusion.** Our study confirmed that transscleral DCPC is a useful, effective and safe procedure with predictable amount of IOP decrease, which makes it the treatment of choice for refractory glaucoma.

Key words: ophthalmologic surgical procedures; glaucoma; laser coagulation; lasers; intraocular pressure; treatment outcome.

Apstrakt

Uvod/cilj. Refraktorni glaukom spada u grupu glaukoma koji ne reaguje na konvencionalnu terapiju. Cilj ove studije bio je da se odredi efekat sniženja intraokularnog pritiska (IOP) kod bolesnika sa refraktornim glaukomom nakon transskleralne ciklofotokoagulacije diodnim laserom. **Metodi.** Ova nerandomizirana, retrospektivna studija obuhvatila je 95 očiju sa refraktornim glaukomom lečenih dioda laser ciklofotokoagulacijom na Klinici za očne bolesti

Kliničkog centra Vojvodine u periodu 2007–2012, prema ustanovljenom protokolu (16–18 pečata, 270°, do 5J energije). Simptomi, vidna oštrina i IOP su praćeni 7 dana, a zatim 1, 3 i 6 meseci nakon lečenja. **Rezultati.** Ukupno 25 bolesnika (95 očiju) bilo je uključeno u studiju, 24 (25,2%) bolesnika sa primarnim (1. grupa) i 71 (74,5%) bolesnik sa sekundarnim (2. grupa) glaukomom. Srednji IOP pre terapije kod obe grupe bio je sličan: 36,08 ± 8,39 mmHg za prvu i 37,36 ± 8,19 mmHg za drugu grupu. Srednje vrednosti IOP za prvu grupu tokom perioda praćenja bile su: 7.

dana $13,96 \pm 8,30$ mmHg (62,1% sniženja), 30. dana $18,44 \pm 8,85$ (48,9% sniženja), nakon 3 meseca $22,44 \pm 7,36$ mmHg (37,8% sniženja), nakon 6 meseci $25,92 \pm 7,65$ mmHg (28,2% sniženja). Srednje vrednosti IOP za drugu grupu tokom perioda praćenja bile su: 7. dana $15,77 \pm 9,73$ mmHg (57,8% sniženja), 30. dana $20,14 \pm 10,20$ mmHg (46,1% sniženja), nakon 3 meseca $23,46 \pm 9,83$ mmHg (37,2% sniženja), i nakon 6 meseci $27,23 \pm 9,87$ mmHg (27,2% sniženja). Bol je pre terapije bio prisutan kod 70 (73,6%) bolesnika, a nakon tretmana kod samo 4 (4,2%) bolesnika. Tegobe kao što su pečenje, osećaj stranog tela,

bockanje, postoperativno su bile prisutne kod 39 (41%) bolesnika. Posle lečenja, tegobe nisu imala 52 (54,7%) bolesnika. **Zaključak.** Naša studija je potvrdila da je transskleralna ciklofotokoagulacija diodnim laserom koristan i efikasan metod u smanjenju IOP, što ga čini terapijom izbora za refraktorni glaukom.

Ključne reči:

hirurgija, oftalmološka, procedure; glaukom; koagulacija laserom; laseri; intraokularni pritisak; lečenje, ishod.

Introduction

Refractory glaucoma is glaucoma resistant to conventional management (maximally tolerated medical therapy, one or more glaucoma surgeries) and glaucoma in cases of neovascularisation after panretinal photocoagulation or cryoablation¹.

Refractory glaucoma are generally treated with cyclodestructive procedures such as: surgical excision of ciliary body, cycloirradiation, cycloelectrolysis, cyclodiathermy, cyclocryotherapy, ultrasound or microwave cyclo-destruction and with Neodymium Yttrium Aluminum Garnet (Nd:YAG) and diode laser cyclophotocoagulation (DCPC)².

Beside refractory primary open and angle closure glaucoma indications for cyclodestructive procedures are: neovascular, post-traumatic, aphakic/pseudophakic glaucoma especially with anterior chamber intraocular lenses (IOL), severe congenital glaucoma with multiple failed surgeries, post-penetrating keratoplasty glaucoma, post-retinal detachment surgery glaucoma, silicone oil induced glaucoma, inflammatory glaucoma.

Mechanism of action of cyclophotocoagulation includes decrease of aqueous production and increase of aqueous outflow³. Destruction of the ciliary epithelium combined with destruction of ciliary blood vessels and coagulative necrosis, leads to decrease in aqueous production⁴. In many cases inflammation after the treatment leads to short-term hypotension⁵.

Neuroepithelial defects created after laser treatment, and creation of transscleral flow similar to cyclodialysis, are responsible for increase of aqueous outflow which is related to the extent of treatment⁶. Diode laser causes destruction of the pigmented and nonpigmented ciliary epithelium and capillaries in the ciliary processes with pigment clumping, coagulative necrosis, and extensive destruction of ciliary muscle with a moderate reduction in vascularity⁷. Some histopathologic studies have shown that diode laser produces most of its coagulative effect on the ciliary body stroma⁸. Even though it is not completely understood, it seems that there is an increase of uveoscleral outflow through the enlarged extracellular spaces from the anterior chamber into the suprachoroidal space⁹.

Diode and Nd:YAG lasers require the presence of ciliary body pigment epithelium for the absorption of laser energy¹⁰. A diode laser (810 nm) has a greater melanin ab-

sorption compared to a Nd:YAG laser (532 nm), requiring lesser energy *per spot*¹¹. Data about dosage and laser treatment protocol-related response vary in available literature^{1,12,13}. A totally delivered energy, the number of laser burns *per session* and pulse power and duration were analyzed in numerous studies, but the results were inconclusive and contradictory. However, most of the results confirmed that refractory glaucoma can be successfully managed on a long-term basis with single or repeated diode laser cyclophotocoagulation¹⁴.

Recently, contact diode laser cryoablation has emerged as the preferred treatment because cryoablation and Nd:YAG laser cyclophotocoagulation are associated with a greater risk of hypotony and phthisis due to excessive ciliary body destruction¹⁵⁻¹⁹.

The aim of the study was to determine the intraocular pressure (IOP) lowering efficacy of transscleral DCPC treatment in the management of pain and IOP in patients with refractory glaucoma.

Methods

This nonrandomized, retrospective study included 95 patients (95 eyes) with refractory glaucoma treated at the University Eye Clinic, Clinical Center of Vojvodina, Novi Sad, Serbia, between November 2007 and November 2012. The study was conducted in accordance with the Declaration of Helsinki. The patients were divided into two groups: the group I – patients with primary glaucoma [primary open angle glaucoma (POAG) and primary angle closure glaucoma (PACG) and group II – patients with secondary glaucoma (neovascular glaucoma, glaucoma post pars plana vitrectomy and traumatic glaucoma)].

All the eyes were treated with transscleral DCPC (Iris Medical OcuLight SLx, Iridex Co, Mountain View, USA). Inclusion criteria were: painful eyes or eyes with other ocular symptoms (burning, itching, foreign body sensation) with elevated IOP and best corrected visual acuity (BCVA) lower than 0.1 according to Snellen. All anti-glaucoma therapeutic modalities (topical, systemic medications), except cyclocryotherapy destructive procedures were tried and rendered unsuccessful. All the patients received retrobulbar or peribulbar anesthesia with 3–5 mL injection of lidocaine hydrochloride alone or in combination with bupivacaine hydrochloride. Cyclophotocoagulation treatment employed diode infrared laser of 810 nm

of wavelength. The average power used was 2.5 W, with 1.5 seconds of duration. Contact tip of G-probe was positioned 1.2 mm behind surgical limbus and 16–18 spots spread over 270° *per* session were made. The sound of “pop” or “snap” at the treatment site was used as indicator for tissue disruption within the ciliary body. To prevent potential inflamma-

main reason for treatment in 25 (26.4%) patients (4 patients in the group I and 21 in the group II). The mean baseline IOP in the two groups was similar: 36.08 ± 8.39 mmHg for the group I and 37.36 ± 8.19 mmHg in the group II. The demographic characteristics and the baseline IOP values are shown in Table 1.

Table 1
Demographics and baseline characteristics of the patients

Variable	Groups of patients	
	Primary glaucoma	Secondary glaucoma
Age (years), $\bar{x} \pm$ SD (min-max)	57.16 ± 10.03 (33–79)	63.12 ± 14.46 (13–86)
Gender, n (%)		
male	13 (54.16)	40 (56.33)
female	11 (45.83)	31 (43.66)
BCVA, n (%)		
0.03–0.1	8 (33.33)	22 (31)
L+P+–0.02	3 (12.5)	17 (23.94)
L-	13 (54.17)	32 (45.07)
Complaints		
pain	20 (83.33)	50 (70.42)
other	4 (16.66)	21 (29.58)
Baseline IOP (mmHg), $\bar{x} \pm$ SD	36.08 ± 8.39	37.36 ± 8.19

BCVA – best corrected visual acuity; IOP – intraocular pressure.

tory reactions topical 1% dexamethasone, every one to two hours while awake, and atropine sulfate 1%, twice a day for the first seven days, were applied in all the patients.

When the patients required repeated treatment due to insufficient reduction in IOP, spots were made in untreated quadrants behind limbus.

The patient's symptoms, BCVA and IOP were recorded 7 days, and 1, 3 and 6 months after the DCPC treatment.

For statistical analyses we used Microsoft Excel software with standard statistical parameters and methods – numerical data were presented using minimum, maximum and average values) standard deviation (SD) and 95% confidence interval (CI). Student's *t*-test was used to make comparison between the groups and to compare IOP values.

Results

A total of 95 patients (95 eyes) were enrolled in this study, of whom 24 (25.2%) were with primary (the group I) and 71 (74.5%) with secondary (the group II) glaucoma. In the group I, there were 20 (21%) patients with POAG and 4 (4.2%) patients with PACG. In the group II 53 (55.7%) patients had neovascular glaucoma, 11 (11.5%) patients had glaucoma after pars plana vitrectomy and 7 (7.3%) patients had traumatic glaucoma.

There was a predominance of males in both groups (55.7% vs 44.3%). The mean age of patients was 61.5 years ($SD \pm 15.4$; range 13–86 years). Forty-five (47.3%) patients were with no light perception (L-). $BCVA \leq 0.1$ was found in 50 (52.7%) patients. There was no significant difference between the treatment groups in the mean age, gender and visual acuity. Pain was the chief complaint and the main reason for treatment in 70 (73.6%) patients (20 patients in the group I and 4 patients in the group II), while other complaints (burning, stinging, foreign body sensation) were the

Mean IOP measurement in the group I showed the following results: on the day 7 it was 13.96 ± 8.30 mmHg (62.1% decrease regarding the baseline volume), on the day 30 it was 18.44 ± 8.85 mmHg (48.9% decrease regarding the baseline value), after 3 months it was 22.44 ± 7.36 mmHg (37.8% decrease from the baseline value), and after 6 months it was 25.92 ± 7.65 mmHg (28.2% decrease regarding the baseline value) (Figure 1).

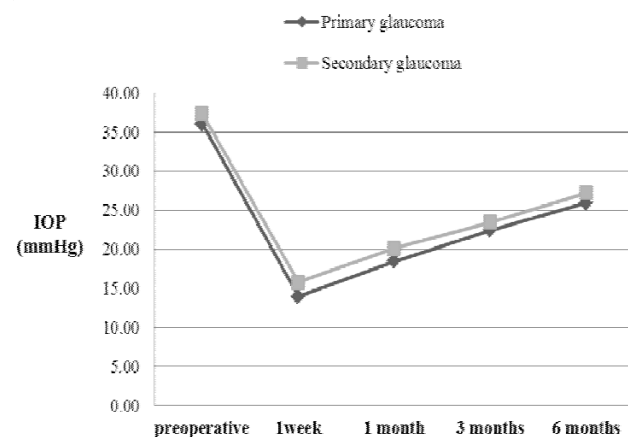


Fig. 1 – Mean intraocular pressure (IOP) by the treatment groups.

Measurement of IOP in the second group showed the following results: on day 7 it was 15.77 ± 9.73 mmHg (57.8% decrease regarding the baseline value), on day 30 it was 20.14 ± 10.20 mmHg (46.1% decrease regarding the baseline value), after 3 months it was 23.46 ± 9.83 mmHg (37.2% decrease regarding the baseline value), and after 6 months it was 27.23 ± 9.87 mmHg (27.2% decrease regarding the baseline regarding) (Figure 1).

During a 6-month follow-up IOP was significantly lower regarding the baseline values in both groups ($p < 0.001$), but there was no significant difference between the two groups.

After the treatment pain persisted in only 4 (4.2%) patients. Other complaints (burning, stinging, foreign body sensation) were postoperatively experienced by 39 (41%) patients. A total of 52 (54.7%) patients had no complaints after the treatment (Figure 2).

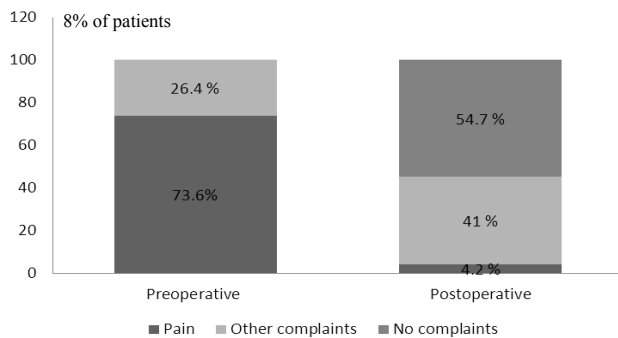


Fig. 2 – Change in chief complaints during the treatment.

Discussion

Transscleral cyclophotocoagulation with a diode laser has gained popularity and has practically replaced the Nd:YAG laser and cryo method for treatment of refractory glaucoma due to comparable efficacy. However, some studies have found that the therapeutic effect can be lost over time and in some cases repeated treatment is necessary²⁰.

There are two factors that determine the laser power – energy and the duration of application. The energy *per* application should be kept under 5 J. A longer duration allows the thermal energy to spread through the tissue and reach the ciliary epithelium¹².

We obtained good results with settings of 2,500 mW and 1.5 seconds of duration (3.75 J), reserving the higher energy levels for repeated procedures and lower settings for eyes with more heavily pigmented irises.

Long-term study of Atallah et al.²¹ in the Manchester Royal Eye Hospital used 1,500 mW with 2.5 seconds of duration. Six months after DCPC IOP reduction was 42% regarding the baseline value. We found a reduction in IOP six

months after the treatment by 28.2% (the group I) and 27.2% (the group II) regarding the baseline values.

Noureddin et al.¹³ showed an IOP decrease in 36 refractory glaucoma eyes from 35.8 mmHg to 19 mmHg (47% regarding the baseline values) which is a higher IOP decrease than our study presented. This difference can be explained by the fact that they performed a 360 degrees cyclophotocoagulation compared to 270 degrees of treatment in our study.

The other study of Hawkins and Stewart²² showed an IOP decrease by 36% after DCPC, from 32.5 mmHg preoperative to 21.8 mmHg six months after the treatment. That is comparable to the results of our study.

Egbert et al.²³ showed a 20% of IOP decrease six months after DCPC in the treatment of refractory POAG. In that study 360 degrees of laser treatment was performed and the energy was 1,500 mW. Our study showed a decrease in IOP in the patients with primary glaucoma of 28.2% regarding the baseline value.

A retrospective analysis of Murphy et al.¹⁴ including 263 eyes with refractory glaucoma after transscleral DCPC, showed that 89% of the patients reached 30% drop in IOP. This overall IOP decrease was similar to our study results. They had found 3% of patients with pain after the treatment. In our study 4.2% of the patients had persistent pain postoperatively due to IOP increase unresponsive to the repeated procedures.

In a multicenter study, 30 eyes of 30 patients with refractory glaucoma were followed for a median of 2 years after DCPC. Seventeen to 19 applications were made over 270 degrees, 2 seconds duration and 1,500–2,000 mW power. IOP fell from a mean baseline pressure of 36.1 mmHg to a mean of 21.6 mmHg and remained essentially unchanged for the duration of the study²⁴. After a 6-month follow-up our study showed comparable results.

Conclusion

Our study confirmed that transscleral diode laser cyclophotocoagulation is a useful, effective and safe procedure with predictable amount of intraocular pressure decrease, which makes it the treatment of choice for refractory glaucoma.

REFERENCES

- Berlin MS. Miscellaneous laser procedures including laser ciliary body therapy. In: *Stamper R, Lieberman MF, Drake MV*, editors. *Becker-Shaffer's Diagnosis and Therapy of the Glaucomas*. 8th ed. Philadelphia, PA: Mosby-Elsevier; 2009. p. 456–7.
- Khalid M, Rafay A, Mirza J, Asim W, Muhammad T, Qazi A. Transscleral Diode Laser Cyclophotocoagulation for the Treatment of Refractory Glaucoma. *Pak J Ophthalmol* 2007; 23(4): 204–8.
- Khomchik OV, Bol'shunov AV, Il'ina TS. Laser cyclodestructive procedures in glaucoma treatment. *Vestn Oftalmol* 2012; 128(3): 54–9. (Russian)
- Subrata M, Ritu G, Jatin A. Diode laser cyclophotocoagulation. *J Curr Glaucoma Pract* 2009; 3(2):47–59.
- van der Zypen E, England C, Fankhauser F, Kwasniewska S. The effect of transscleral laser cyclophotocoagulation on rabbit ciliary body vascularization. *Graefes Arch Clin Exp Ophthalmol* 1989; 227(2): 172–9.
- Schubert HD, Federman JL. A comparison of CW Nd: YAG contact transscleral cyclophotocoagulation with cyclocryopexy. *Invest Ophthalmol Vis Sci* 1989; 30(3): 536–42.
- Liu G, Mizukawa A, Okisaka S. Mechanism of intraocular pressure decrease after contact transscleral continuous-wave Nd:YAG laser cyclophotocoagulation. *Ophthalmic Res* 1994; 26(2): 65–79.

8. Hennis HL, Stewart WC. Semiconductor diode laser transscleral cyclophotocoagulation in patients with glaucoma. *Am J Ophthalmol* 1992; 113(1): 81–5.
9. Agarwal HC, Gupta V, Sibota R. Evaluation of contact versus non-contact diode laser cyclophotocoagulation for refractory glaucomas using similar energy settings. *Clin Experiment Ophthalmol* 2004; 32(1): 33–8.
10. Cantor LB, Nichols DA, Katz LJ, Moster MR, Poryzges E, Shields JA, et al. Neodymium-YAG transscleral cyclophotocoagulation. The role of pigmentation. *Invest Ophthalmol Vis Sci* 1989; 30(8): 1834–7.
11. Schubert HD, Agarwala A, Arbizio V. Changes in aqueous outflow after in vitro neodymium: yttrium aluminum garnet laser cyclophotocoagulation. *Invest Ophthalmol Vis Sci* 1990; 31(9): 1834–8.
12. Morrison J, Pollack I. Cyclodestruction. In: Morrison J, Pollack I, editors. *Glaucoma: Science and practice*. New York: Thieme; 2003. p. 448–55.
13. Nonreddin BN, Zein W, Haddad C, Ma'luf R, Bashshur Z. Diode laser transcleral cyclophotocoagulation for refractory glaucoma: a 1 year follow-up of patients treated using an aggressive protocol. *Eye (Lond)* 2006; 20(3): 329–35.
14. Murphy CC, Burnett CA, Spry PG, Broadway DC, Diamond JP. A two centre study of the dose-response relation for transscleral diode laser cyclophotocoagulation in refractory glaucoma. *Br J Ophthalmol* 2003; 87(10): 1252–7.
15. Mastrobattista JM, Luntz M. Ciliary body ablation: where are we and how did we get here. *Surv Ophthalmol* 1996; 41(3): 193–213.
16. Benson MT, Nelson ME. Cyclocryotherapy: a review of cases over a 10-year period. *Br J Ophthalmol* 1990; 74(2): 103–5.
17. Schuman JS, Bellows AR, Shingleton BJ, Latina MA, Allingham RR, Belcher CD, et al. Contact transscleral Nd:YAG laser cyclophotocoagulation. *Ophthalmology* 1992; 99(7): 1089–95.
18. Ulbig MW, McHugh DA, McNaught AI, Hamilton AM. Clinical comparison of semiconductor diode versus neodymium: YAG non-contact cyclo photocoagulation. *Br J Ophthalmol* 1995; 79(6): 569–74.
19. Iliev ME, Gerber S. Long-term outcome of trans-scleral diode laser cyclophotocoagulation in refractory glaucoma. *Br J Ophthalmol* 2007; 91(12): 1631–5.
20. Rosentreter A, Gaki S, Lappas A, Cursiefen C, Dietlein TS. Previous cyclodestruction is a risk factor for late-onset hypotony and suprachoroidal haemorrhage after glaucoma drainage device surgery. *Br J Ophthalmol* 2013; 97(6): 715–9.
21. Ataullah S, Biswas S, Artes PH, O'Donoghue E, Ridgway AE, Spencer AF. Long term results of diode laser cycloablation in complex glaucoma using the Zeiss Visulas II system. *Br J Ophthalmol* 2002; 86(1): 39–42.
22. Hawkins TA, Stewart WC. One-year results of semiconductor transscleral cyclophotocoagulation in patients with glaucoma. *Arch Ophthalmol* 1993; 111(4): 488–91.
23. Egbert PR, Fiadoyor S, Budenz DL, Dadzije P, Byrd S. Diode laser transscleral cyclophotocoagulation as a primary surgical treatment for primary open-angle glaucoma. *Arch Ophthalmol* 2001; 119(3): 345–50.
24. Kosoko O, Gaasterland DE, Pollack IP, Enger CL. Long-term outcome of initial ciliary ablation with contact diode laser transscleral cyclophotocoagulation for severe glaucoma. The Diode Laser Ciliary Ablation Study Group. *Ophthalmology* 1996; 103(8): 1294–302.

Received on December 13, 2013.

Revised on December 25, 2013.

Accepted on January 27, 2013.