



Long term complications of ventilation tube insertion in children with otitis media with effusion

Dugotrajne komplikacije implantacije ventilacionih cevčica u lečenju hroničnog sekretornog otitisa u dečjem uzrastu

Vladimir Djordjević*†, Bojana Bukurov†, Nenad Arsović*†, Snežana Ješić*†,
Jovica Milovanović*†, Vladimir Nešić*†

*Faculty of Medicine, University of Belgrade, Belgrade, Serbia; †Clinic for
Otorhinolaryngology and Maxillofacial Surgery, Clinical Center of Serbia, Belgrade,
Serbia

Abstract

Background/Aim. Otitis media with effusion (OME) is characterized by the prolonged presence of fluid (longer than 12 weeks) of different viscosity in the middle ear, without perforation of the eardrum or signs of acute inflammation. The conservative treatment does not always provide satisfactory recovery, so surgical treatment may be unavoidable. The aim of the study was to determine the incidence, type and frequency of complications caused by ventilation tube insertion as a part of treatment for OME in children, and specifically, to evaluate the evolution of these changes over the extended period of time. **Methods.** During a 5-year period (1986–1991), 84 children with chronic bilateral OME, aged from 6 months to 12 years, were enrolled in the study and treated with ventilation tube insertion. All the patients were periodically checked every 6 months over a 3–8 year period following the intervention (otomicroscopic examination, audiometry, tympanometry), and reexamined in 2013 (22–27 years after the primary surgical intervention). **Results.** The complications observed in this study (51%) were atrophic scarring of the tympanic membrane, myringo- and tympanosclerosis, retraction of the eardrum, persistent perforations, granulation tissue formations, development of chronic otitis and sensorineural hearing loss. **Conclusion.** The incidence of complications after ventilation tube insertion was 51% in this study. Atrophic scars and myringosclerosis were the most prominent complications. Despite high complications rate ventilation tube insertion still remains the treatment of choice in children with otitis media with effusion.

Key words:

otitis media with effusion; otologic surgical procedures; middle ear ventilation; treatment outcome; child.

Apstrakt

Uvod/Cilj. Hronični sekretorni otitis definiše se kao produženo prisustvo sekreta (duže od 12 nedelja) različite gustine u srednjem uvu, bez perforacije na bubnoj opni ili znakova zapaljenja. Kako konzervativno lečenje često ne daje zadovoljavajuće rezultate, hirurška intervencija može biti neizbežna. Cilj ovog rada bio je da se odredi incidencija, tip i učestalost komplikacija nakon hirurškog lečenja (implantacije ventilacionih cevčica) kao dela lečenja dece sa ovim oboljenjem, kao i da se proceni evolucija ovih promena u produženom vremenskom periodu. **Metode.** Tokom petogodišnjeg perioda (1986–1991) 84 dece sa obostranim sekretornim otitisom, uzrasta od 6 meseci do 12 godina bilo je uključeno u studiju i lečeno implantacijom ventilacionih cevčica. Sva deca su praćena i periodično kontrolisana 3–8 godina nakon intervencije (otomikroskopski pregled, audiometrija, timpanometrija) i ponovo pregledana tokom 2013. godine, odnosno 22–27 godina nakon primarne hirurške intervencije. **Rezultati.** Registrovane komplikacije u ovoj studiji (51%) bile su atrofični ožiljci, timpano- i miringoskleroz, različiti stepeni retrakcije bubne opne, granulaciono tkivo, razvoj hroničnog otitisa i pojava senzorneuralne naglušnosti. **Zaključak.** Učestalost pojave komplikacija nakon implantacije ventilacionih cevčica vrlo je visoka, u našoj studiji iznosila je 51%. Najčešće komplikacije bili su atrofični ožiljci na bubnoj opni i miringoskleroz. Iako je broj komplikacija veliki, implantacija ventilacionih cevčica i dalje ostaje terapija izbora u lečenju dece sa hroničnim sekretornim otitisom.

Ključne reči:

otitis media, serozni; hirurgija, otološka, procedure; uvo, srednje, aeracija; lečenje, ishod; deca.

Introduction

Otitis media with effusion (OME) is characterized by the prolonged presence of fluid of different viscosity in the middle ear, without perforation of the eardrum or signs of acute inflammation. This fluid (secretion) can cause limited mobility of tympanic ossicular chain. It is most commonly seen in childhood, between the ages of 7 months and 6 years, with a higher prevalence during winter months¹. The disease has usually slow and silent course with the symptoms that are vague and in most cases not clinically significant, while its etiology still remains unclear. When the condition is misdiagnosed or not treated adequately, it can lead to serious consequences and impair function of stato-acoustic apparatus. Considering the fact that the condition is almost always bilateral, long lasting hearing loss can have great impact on psychokinetic and speech development in childhood. Children with persistent OME are usually hyperactive, inattentive, with different behavioral problems and usually have decreased quality of life compared to their peers^{2,3}.

Conservative treatment does not always provide adequate recovery. In these cases, surgical treatment may be inevitable, including ventilation tube insertion, with or without adenoidectomy. Myringocentesis and ventilation tube insertion are still commonly performed in everyday ear, nose and throat practice, and the possibility of complications is evident; therefore, it is very important to identify advantages and disadvantages of this surgical procedure.

Possible late complications of ventilation tube insertion reported in the literature are: persistent otorrhea, persistent perforation of the eardrum, atrophic scars, tympano- or myringosclerosis with or without ossicular chain fixation, granulation tissue, cholesteatoma, and sensorineural hearing loss^{4,5}. Some authors reported various eardrum changes following this procedure in as much as 80% of cases⁵. It is important to note that many of these complications may result from the disease itself.

The aim of this study was to determine the incidence, type and frequency of complications caused by ventilation tube insertion as a part of treatment for OME in children, and specifically, to evaluate the evolution of these changes over the extended period of time.

Methods

During a 5-year period (1986–1991), 84 children with chronic bilateral OME, aged from 6 months to 12 years, were enrolled in the study and treated with ventilation tube insertion. In most cases (in 157 of 165 ears), “Tübingen“ gold prosthesis was implanted, most commonly in anterior inferior quadrant (86.06%), and in rest of the cases in anterior superior quadrant (13.94%). In 30.3% of cases, reimplantation was performed, while 14.54% of patients underwent the intervention more than twice. Average aeration time was 8 months and 21 days. All the patients were periodically checked, every 6 months, over a 3–8 year period following the intervention (otomicroscopic examination, audiometry,

tympanometry), and reexamined in 2013 (22–27 years after the primary surgical intervention). A total of 71 patients came to reexamination visit.

Statistical analysis included descriptive methods of recording absolute and relative frequencies of the observed features, as well as hypothesis testing and determining the level of significance using Pearson’s χ^2 test and Fisher’s exact test. The level of correlation was determined using the contingency coefficient (C).

Results

The study found that incidence of various complications of ventilation tube insertion after extended period of time was 51%.

In the early postoperative period, atrophic areas formed, usually occupying small areas (up to 3 mm), except in 4 cases were they involved almost half of the eardrum, and 4 other cases were they involved the entire surface of the tympanic membrane. Furthermore, there were 2 cases of eardrum perforation due to the atrophic scarring. At the last examination, all cases showed atrophic areas localized exclusively in the anterior inferior quadrant of the eardrum, involving area of up to 3 mm in diameter.

In the early postoperative period, mild retraction of the tympanic membrane was also observed, involving anterior part of the membrane in 3 cases, and posterior superior quadrant in 3 other cases. On the later reexamination, from 2 cases, which both had retraction situated in upper portion of the membrane, one of them had a form of retraction pocket.

Tympanosclerotic scars at sites of previously implanted ventilation tubes were observed in 25 cases at previous follow-up examinations, and 15 of them spread more extensively over the membrane, involving less than half of its surface. In adulthood, these scars were present at the exact locations and with the same extent as in the past period.

In the cases of 6 verified persistent perforations, there were no observable signs of inflammatory process in the ear, and myringoplasties were performed at adolescent age. In 5 remaining cases, chronic suppurative otitis developed; 3 patients had severe sensorineural hearing loss, in 3 cases extensive polypous granulomatous process of the middle ear’s mucosa was confirmed, while 2 patients developed cholesteatoma (one with protympanic localization, and the other with extensive features).

All of these cases were treated with surgical procedures (in one case with 2 reinterventions). On the latter reexamination, in adulthood, only 2 patients had pathological findings, one case of the radical trepanation, and one tympanic membrane perforation. In the rest of the cases, otologic findings showed no abnormalities. On reexamination, we observed new case of chronic suppurative otitis in adulthood, which was surgically treated at other hospital (Table 1).

In 80 (48.48%) ears in early adolescence and 76 (54.28%) in adulthood no complications were observed. The patients did not have any symptoms and their otomicroscopic, audiometric and tympanometric findings were normal.

Table 1
Complications 3–8 years and 22–27 years after the implantation

Complications	Ear, n (%)	
	after 3–8 years	after 22–27 years
Atrophy of the eardrum	48 (29.09)	15 (10.71)
Tympanosclerosis	42 (25.45)	35 (25.00)
Persistent perforation	11 (6.66)	3 (2.14)
Retraction	6 (3.63)	2 (1.42)
Granulation tissue	3 (1.81)	/ /
Sensorineural hearing loss	3 (1.81)	3 (2.14)
Cholesteatoma	2 (1.21)	/ /
No complications	80 (48.48)	76 (54.28)

Figure 1 clearly shows a significant correlation between repeated myringocentesis on the same ear and later occurrence of atrophy and tympanosclerosis of eardrum. In regard to the incidence of remaining complications, frequencies were low, and with statistical testing, these differences compared to the number of myringocentesis with ventilation tube insertion in the same ear, showed no significant difference ($p < 0.05$).

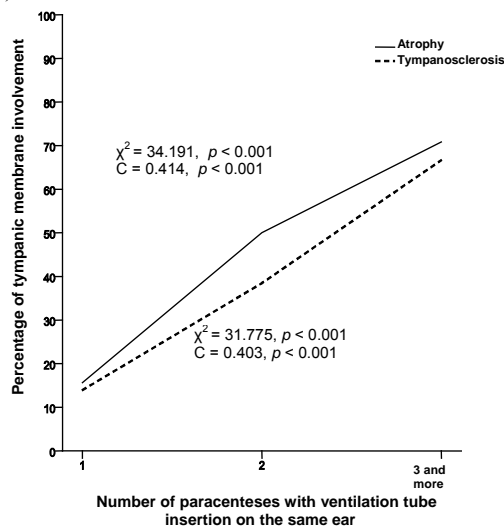


Fig. 1 – A correlation between the frequencies of atrophy/tympanosclerosis of the tympanic membrane and the number of myringocenteses with ventilation tube insertion in the same ear.

Discussion

Although the earlier presumption that implantation of ventilation tubes in children with bilateral OME has a beneficial effect on hearing, it was shown that the procedure is only of short duration efficacy, and researchers failed to prove that it has any impact on speech and language development in these children^{6–8}.

Atrophic areas on the tympanic membrane are the most frequent complication of ventilation tube insertion in our study. They appear when the tissue repair is inadequate due to the lack of middle layer of the membrane, and they are localized to the site of previous tube implantation. In the cases of reimplantation, this complication was more frequent. The prevalence of segmental atrophy in ears where ventilation tubes were implanted can vary between 16% and 74%, while

certain percent of these changes is seen in ears that had never been implanted (up to 30%)^{9,10}. Progression of these scars is possible in the first couple of years after the extraction, which can lead to more serious complications in the future if middle ear ventilation remains poor – retraction pocket formation, atelectasis, and cholesteatoma. According to our results, these scars are in most cases minimal and without change, with rare tendency of further development. After a longer follow-up period, a significant number of these changes resolved.

Atrophic scars and pars flaccida retraction pockets were not common in early postoperative period, and in adulthood the occurrence was even lower. The observed low incidence of development is probably due to the normalization of middle ear ventilation in most cases after implantation. These changes are also considered to be complications of the disease itself by some authors¹¹.

Tympano(myringo)sclerosis is the second most common complication. It represents hyaline degeneration and calcification of the fibrous layer beyond the mucosa. In cases of reimplantation these changes appeared more frequently, and progressed in 10 of 42 cases in the first couple of years after the intervention, which is in accordance with reported findings by other authors¹². After this period, these scars become stable and permanent, and lose the tendency both of progression and regression. It is debated in literature whether these changes are sequelae of the disease itself or represent a complication of previously implanted ventilation tube. The estimated risk ratio for the development of myringosclerosis at the site of previously implanted ventilation tube is 24.5%⁹.

In our opinion, persistent perforations, in half of the cases when they are “dry”, with normal otomicroscopic findings in the tympanic cavity, represent the treatment optimum because they allow for prolonged aeration. The reported prevalence of this complication in the literature is around 3%¹³. In these cases, myringoplasty should be delayed until the adolescent period, with regular follow-ups. In cases of chronic otitis or cholesteatoma development, the surgery should be performed earlier.

The observed causal connection between the ventilation tube insertion and latter occurrence of cholesteatoma in 2 cases is still unsolved. The possible causes are epithelial migration in tympanic cavity over the edges of the perforation and retraction pocket formation on the atrophic tympanic membrane after the extraction. The prevalence of this serious complication is reported to be 1.1%¹⁴. It is considered that implantation of ventilation tubes can be complicated by the development of cho-

lesteatoma or it is a sequelae of the disease itself. The incidence of cholesteatoma formation is significantly higher in patients with poor Eustachian tube function. The development of cholesteatoma is most probably sequelae of both the disease and surgical intervention. Although a serious complication, chronic otitis can be managed and stabilized till adulthood if diagnosed and surgically treated in a timely manner.

Conclusion

The incidence of complications after ventilation tube implantation is very high, reaching 51% in our cases, but

they are mostly mild with no significant pathological or functional consequences. Atrophy and tympano (myringo) sclerosis are the most common complications. Several years after the intervention, these changes can progress, but they tend to stabilize as time passes. Persisting perforations, cholesteatoma and sensorineural hearing loss are uncommon but serious complications that require surgical treatment. Considering that myringocentesis with ventilation tube implantation leads to functional and morphological healing of the ear and that serious complications are rare, this intervention still represents treatment of choice for chronic otitis media with effusion.

R E F E R E N C E S

1. *Midgley EJ, Dewey C, Pryce K, Maw AR.* The frequency of otitis media with effusion in British pre-school children: a guide for treatment. ALSPAC Study Team. *Clin Otolaryngol Allied Sci* 2000; 25(6): 485–91.
2. *Bennett KE, Haggard MP.* Behaviour and cognitive outcomes from middle ear disease. *Arch Dis Child* 1999; 80(1): 28–35.
3. *Rosenfeld RM, Goldsmith AJ, Tetlus L, Balzano A.* Quality of life for children with otitis media. *Arch Otolaryngol Head Neck Surg* 1997; 123(10): 1049–54.
4. *Kalcioglu MT, Cokkeser Y, Kizilay A, Ozguran O.* Follow-up of 366 ears after tympanostomy tube insertion: why is it draining. *Otolaryngol Head Neck Surg* 2003; 128(4): 560–4.
5. *Vlastarakos PV, Nikolopoulos TP, Korres S, Tavoulari E, Tzagaroulakis A, Ferekidis E.* Grommets in otitis media with effusion: the most frequent operation in children. But is it associated with significant complications. *Eur J Pediatr* 2007; 166(5): 385–91.
6. *Browning GG, Rovers MM, Williamson I, Lous J, Burton MJ.* Grommets (ventilation tubes) for hearing loss associated with otitis media with effusion in children. *Cochrane Database Syst Rev* 2010; (10): CD001801.
7. *Yaman H, Yilmaz S, Alkan N, Subasi B, Guclu E, Ozturk O.* Shepard grommet tympanostomy tube complications in children with chronic otitis media with effusion. *Eur Arch Otorhinolaryngol* 2010; 267(8): 1221–4.
8. *Khodaverdi M, Jorgensen G, Lange T, Stangerup S, Drozdziemiński D, Tos M, et al.* Hearing 25 years after surgical treatment of otitis media with effusion in early childhood. *Int J Pediatr Otorhinolaryngol* 2013; 77(2): 241–7.
9. *Johnston LC, Feldman HM, Paradise JL, Bernard BS, Colborn DK, Casselbrant ML, et al.* Tympanic membrane abnormalities and hearing levels at the ages of 5 and 6 years in relation to persistent otitis media and tympanostomy tube insertion in the first 3 years of life: A prospective study incorporating a randomized clinical trial. *Pediatrics* 2004; 114(1): 58–67.
10. *Schilder AG, Hak E, Straatman H, Zielhuis GA, van Bon WH, van den Broek P.* Long term effects of ventilation tubes for persistent otitis media with effusion in children. *Clin Otolaryngol Allied Sci* 1997; 22(5): 423–9.
11. *Maw AR, Bawden R.* Tympanic membrane atrophy, scarring, atelectasis and attic retraction in persistent, untreated otitis media with effusion and following ventilation tube insertion. *Int J Pediatr Otorhinolaryngol* 1994; 30(3): 189–204.
12. *Maw AR.* Development of tympanosclerosis in children with otitis media with effusion and ventilation tubes. *J Laryngol Otol* 1991; 105(8): 614–7.
13. *Golz A, Netzer A, Joachims HZ, Westerman ST, Gilbert LM.* Ventilation tubes and persisting tympanic membrane perforations. *Otolaryngol Head Neck Surg* 1999; 120(4): 524–7.
14. *Golz A, Goldenberg D, Netzer A, Westerman LM, Westerman ST, Fradis M, et al.* Cholesteatomas associated with ventilation tube insertion. *Arch Otolaryngol Head Neck Surg* 1999; 125(7): 754–7.

Received on December 10, 2013.

Revised on January 6, 2014.

Accepted on January 24, 2014.

On Line-First June, 2014.